V Konferencja

IMMUNOTERAPIA NOWOTWORÓW

Warszawa, 10–11 stycznia 2019 roku

patronage:

VIA MEDICA

tvmed

ikamed.pl
internetowa księgarnia medyczna

Beni Gesundheit MD PhD,
RAPO YERAPEH Ltd., ISRAEL
b.gesund@gmail.com
+972-506-558-638
www.RapoYerape.com

rapo yerape Ltd.
Spreading Hope Virally

PRESENTATION OUTLINE

1. **GBM – Treatments, Challenges & Outcome**
2. **GBM: New Strategies with OV, DC, CPI**
3. **GBM and OV – Presentation of 4 Patients**
4. **Discussion of the New GBM Protocol**

   & Clinical OV Program

Incidence by Age / 100,000

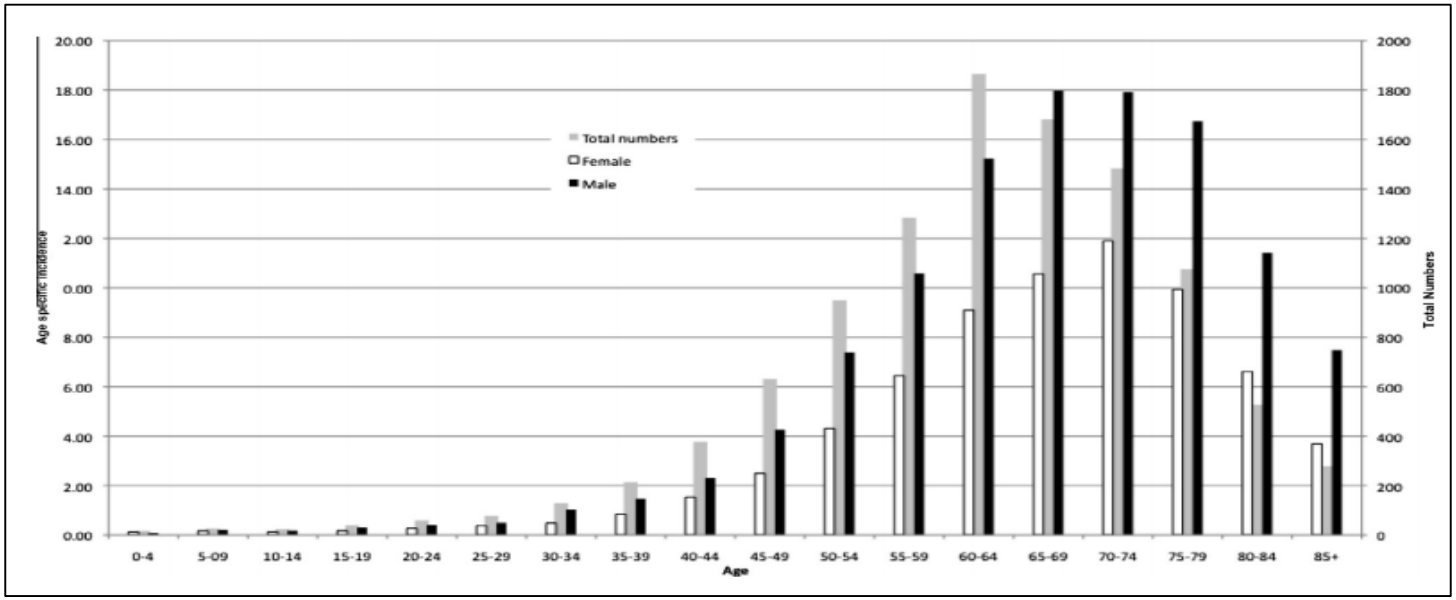

Median Survival in mohts by Age

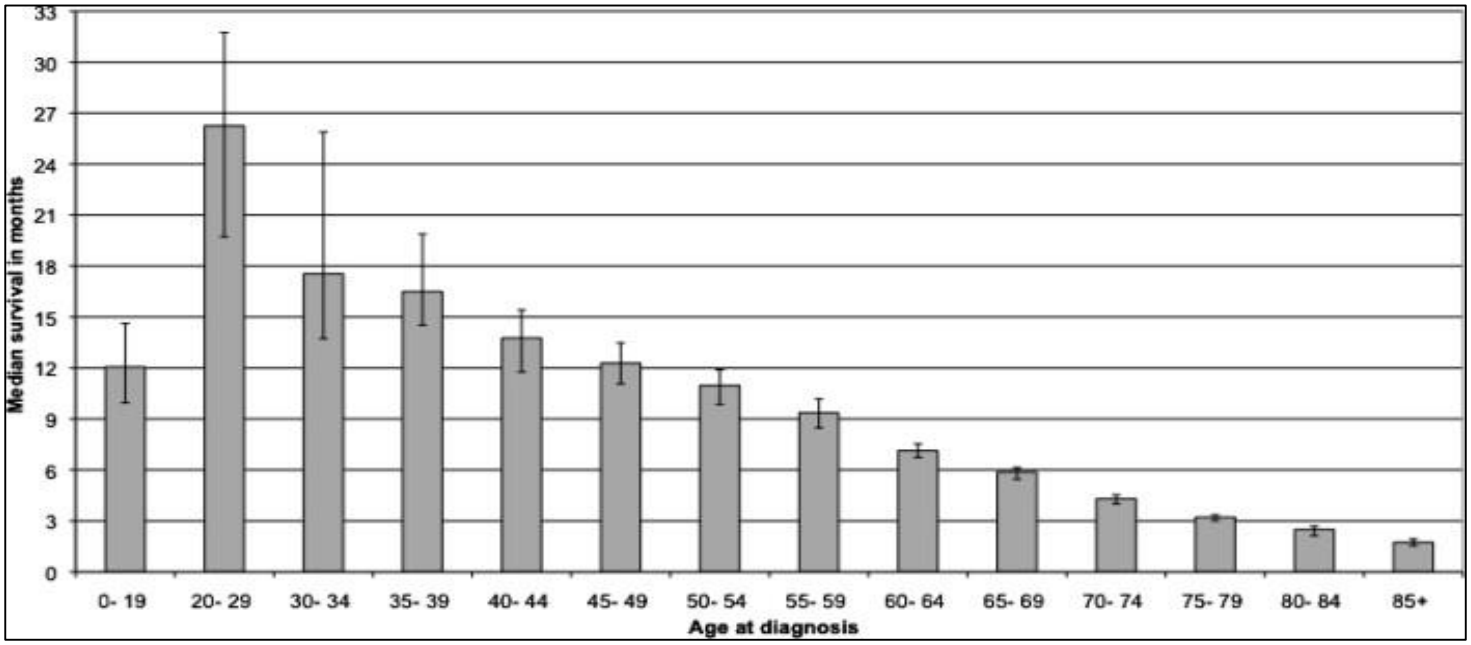

Brodbelt A, et al: lioblastoma in England: 2007-2011. Eur J Cancer. 2015;51(4):533-42.

Common GBM therapies

Roger Stupp Protocol

Maximum Safe Resection

(+Wafer with carmustine)

Radiation

60 Gy in 30 fractions
5d/w x 6 week

Chemotherapy

MGMT methylation → temozolomide TMZ
75 mg/m²/d during RT +
150-200 mg/m² 5d/mon

The NEW ENGLAND JOURNAL of MEDICINE

ORIGINAL ARTICLE

Radiotherapy plus Concomitant and Adjuvant Temozolomide for Glioblastoma

Roger Stupp, M.D., Warren P. Mason, M.D., Martin J. van den Bent, M.D.,

N ENGL J MED 352;10 WWW.NEJM.ORG MARCH 10, 2005

1. GBM: Classical Treatment & Survival

Radiotherapy plus Concomitant and Adjuvant Temozolomide for Glioblastoma

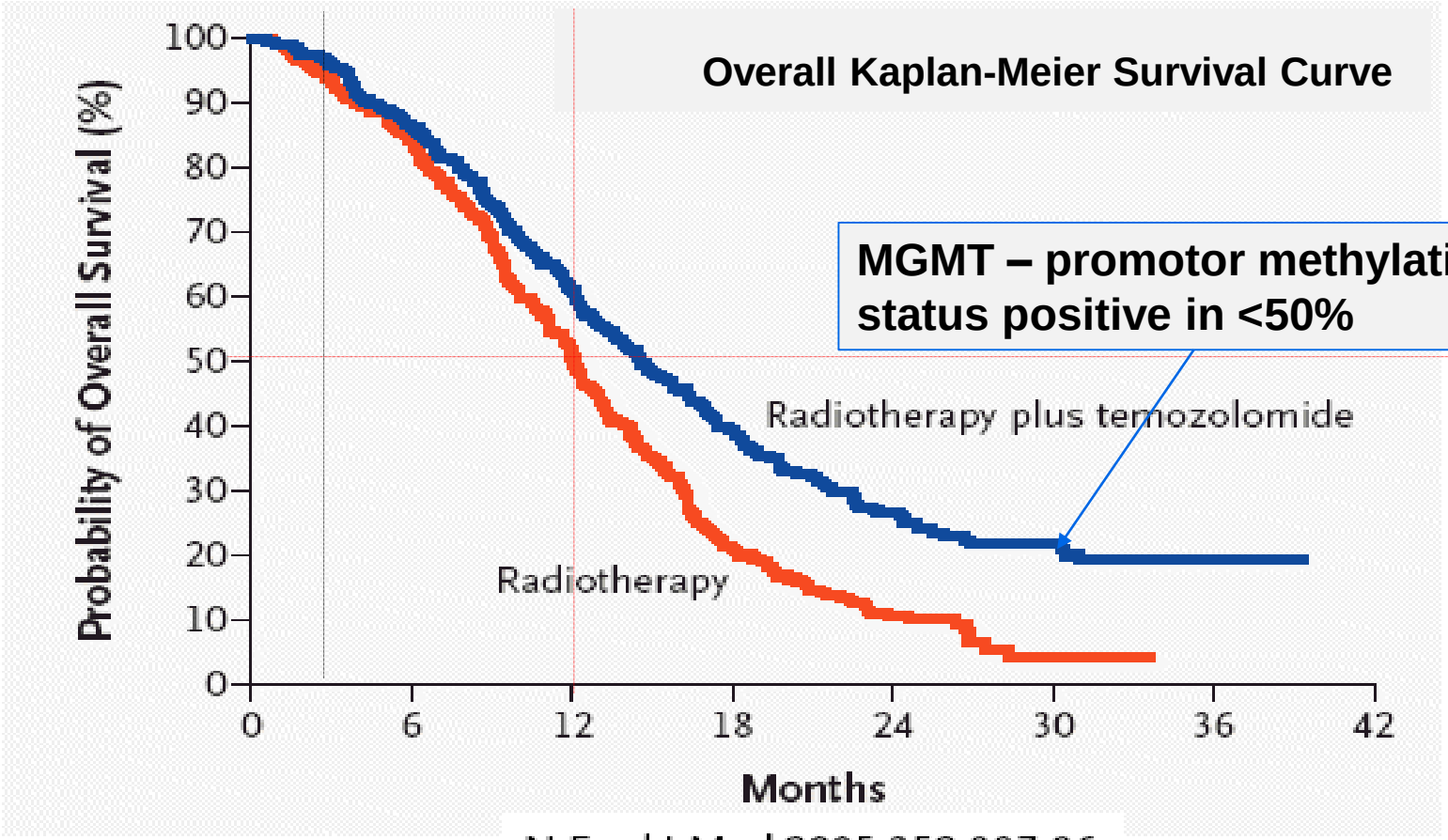

MGMT – promotor methylation status positive in <50%

N Engl J Med 2005;352:987-96.

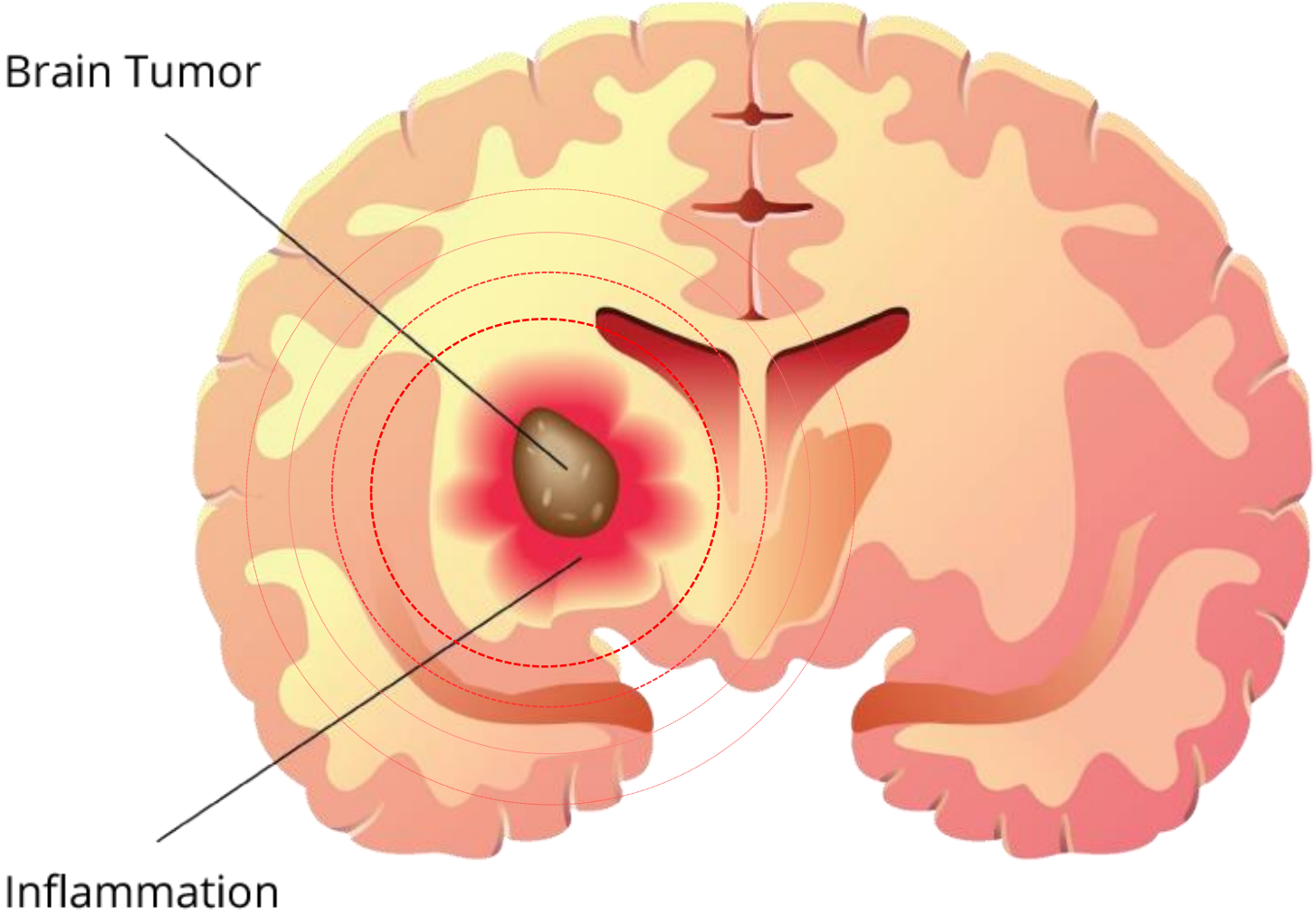

- ±Refractory to Chemotherapy
- BBB = Blood Brain Barrier
- BTB = Brain Tumor Barrier
- Micrometastasis = Total Brain disease

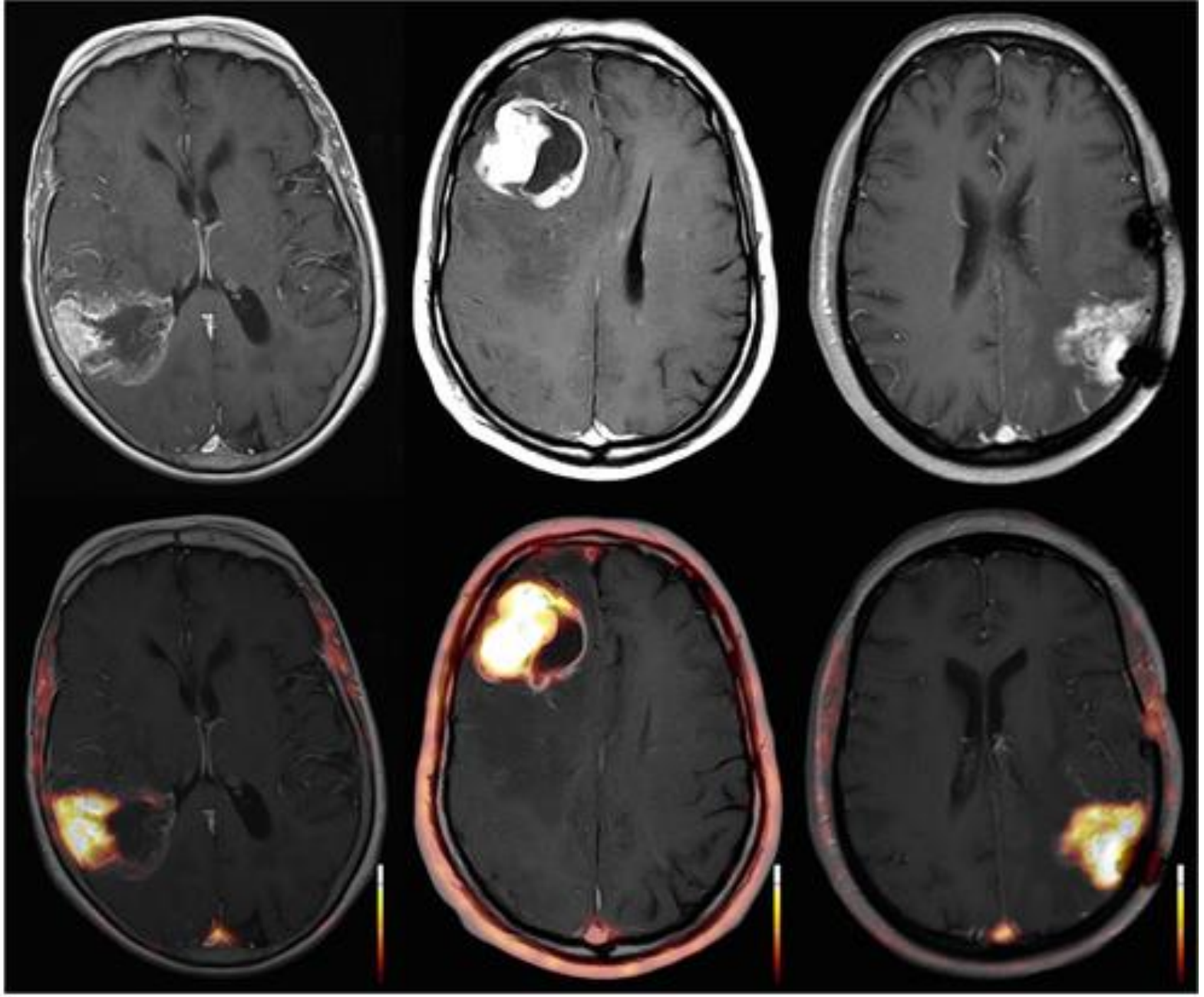
MRI
T1 +KM
PET/MRI
fusion
Patient 2
Patient 3
Patient 15

PRESENTATION OUTLINE

1. **GBM – Treatments, Challenges & Outcome**
2. **GBM: New Strategies with OV, DC, CPI**
3. **GBM and OV – Presentation of 4 Patients**
4. **Discussion of the New GBM Protocol**

   & Clinical OV Program

New Strategies:
Chemotherapy & Oncolytic viruses



“His genius was essentially practical, and his military concepts evolved from **the close study of earlier commanders**… He made the **fullest use of the ideas of his predecessors and breathed life into them**."

(*Chandler - "Dictionary of the Napoleonic wars" p 18*)

Immunotherapy for Cancer

(I) 47y F Melanoma of foot, no metastasis
⇨wide surgical Resection

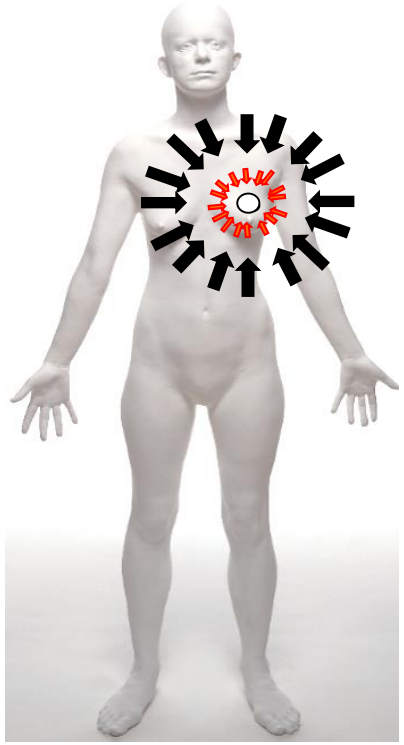

(II) 3y later: adeno-ca of breast => surgical resection and radiation to breast and axillary lN



(III) 1 mo later: Multiple sc melanoma nodules in irradiated field
=> Visceral spread
=> fatal disease

Woodruff MF .Immunological Aspects of Cancer. Lancet 1964;2:265-270

“Classical” Cancer Treatments

- **Surgery**
- **Cyto-toxic = Chemotherapy**
- **Radiotherapy**

✓ **“Efficient”**
✓ **Fast**
➢ *Aggressive*
➢ *Toxic/Dose limiting*
➢ *Tolerance*
➢ *Immunosuppressive*
➢ *Morbidity/Mortality*
➢ *Refractory: MRD*





“Biological” Cancer Treatments

- **Immunology**
- **Anti-body**
- **Virotherapy**
- **Hyperthermy**
- **etc.**

✓ **Tolerance: Slow, long term**
✓ **Immune modulating**
✓ **Good for MRD**
➢ *“No” fast Effect*



“Classical” Cancer Treatments

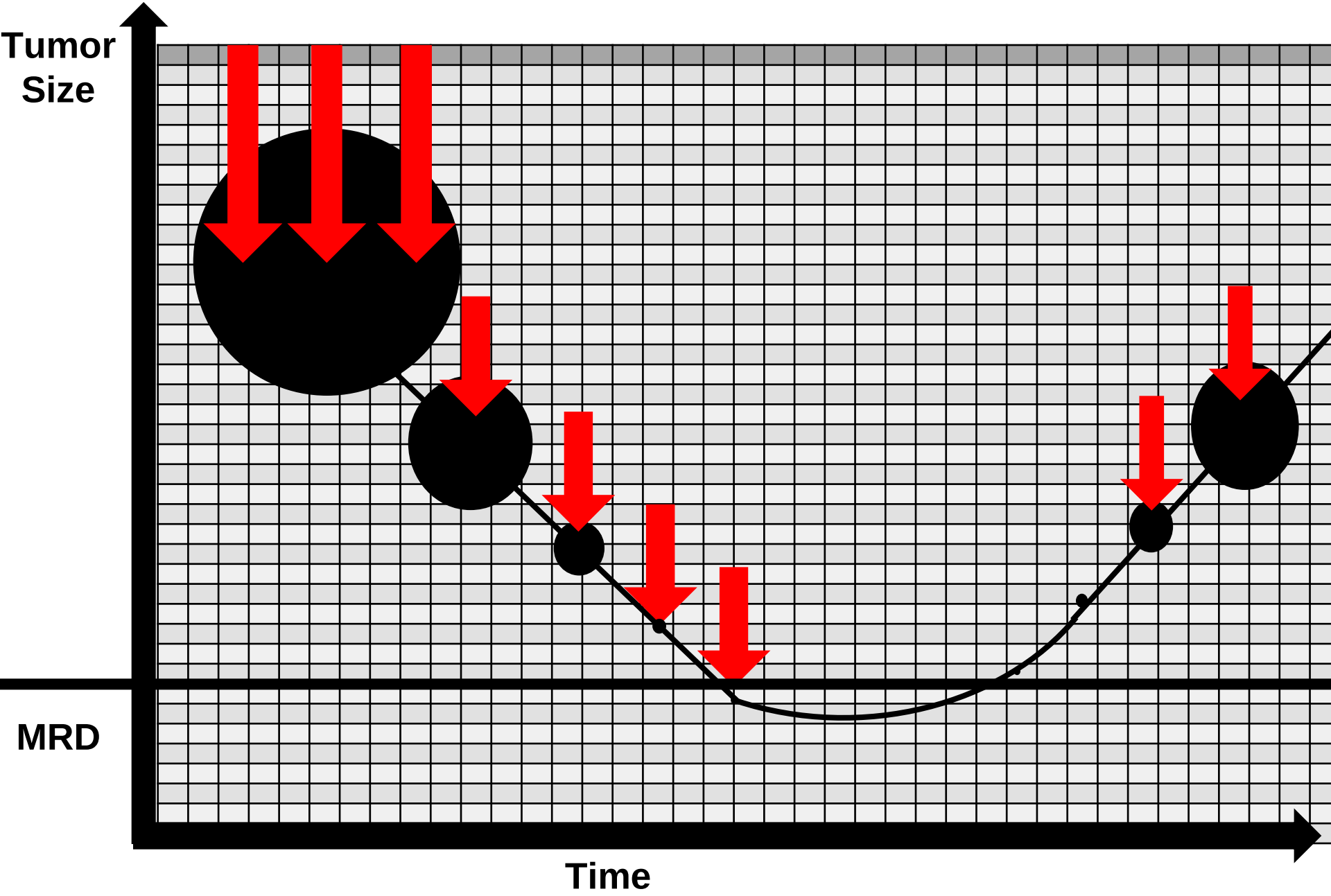

“Classical” Cancer Treatments

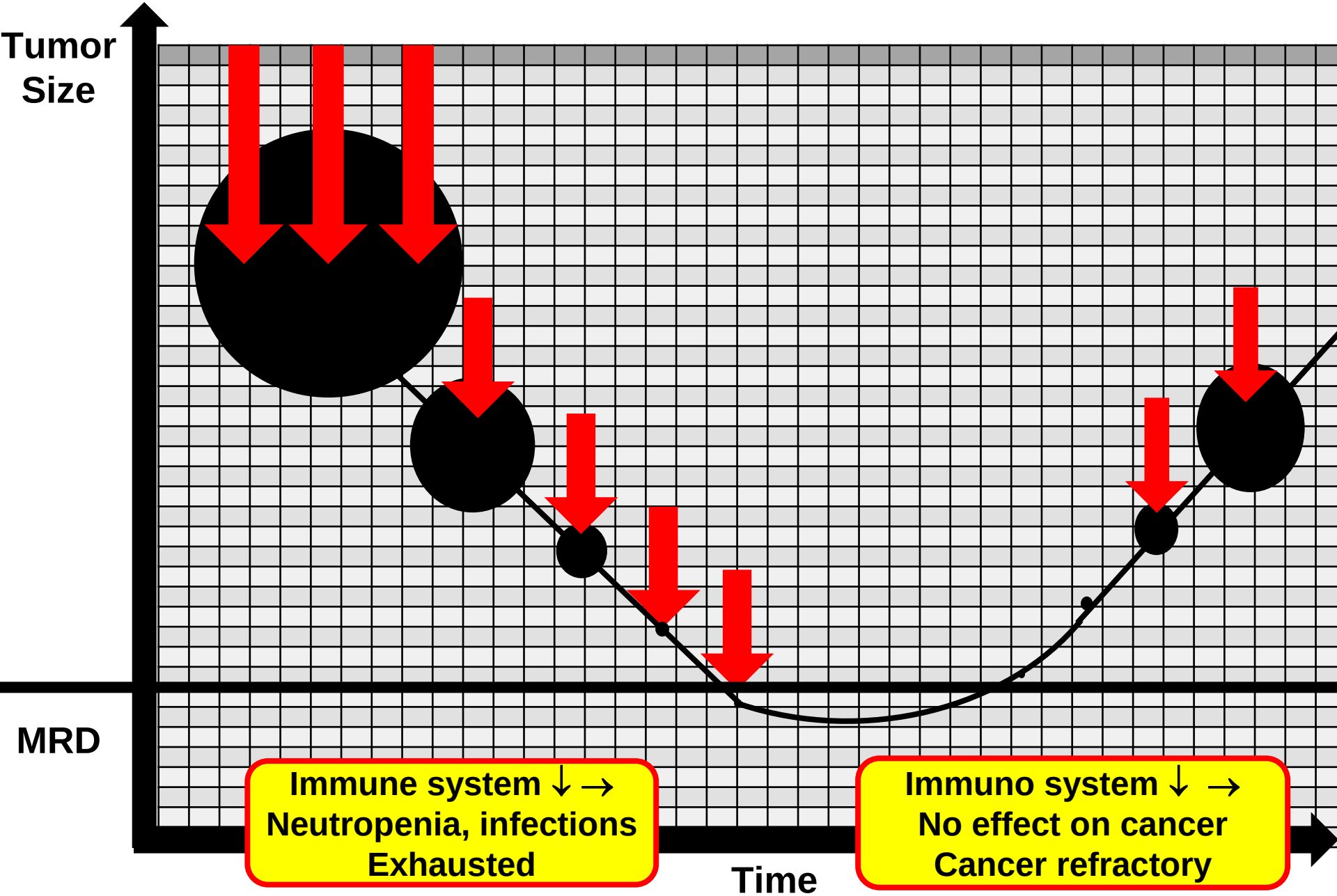

“Classical” & “Biological” Treatments

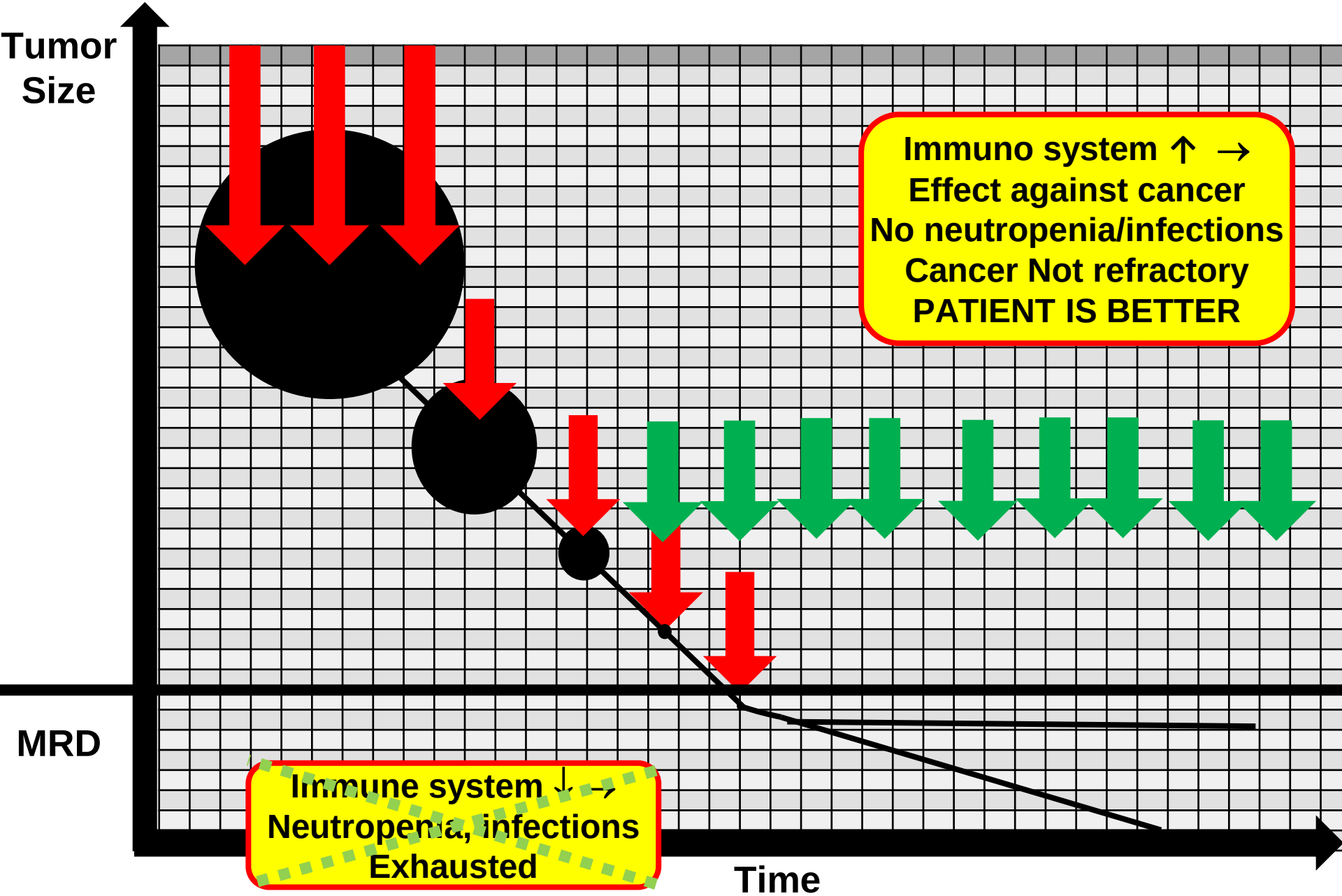

frontiers Research Topics

frontiers

Download Ebook PDF | Download Ebook EPUB

www.frontiersin.org

Overview | 17 Articles | 82 Authors | Impact | Comments

VIEWS 66,147

ONCOLYTIC VIRUSES—GENETICALLY ENGINEERING THE FUTURE OF CANCER THERAPY

EDITED BY: Benjamin Gesundheit and Joshua P. Rosenzweig

PUBLISHED IN: Frontiers in Oncology and Frontiers in Immunology

Oncolytic viruses (OV) – History

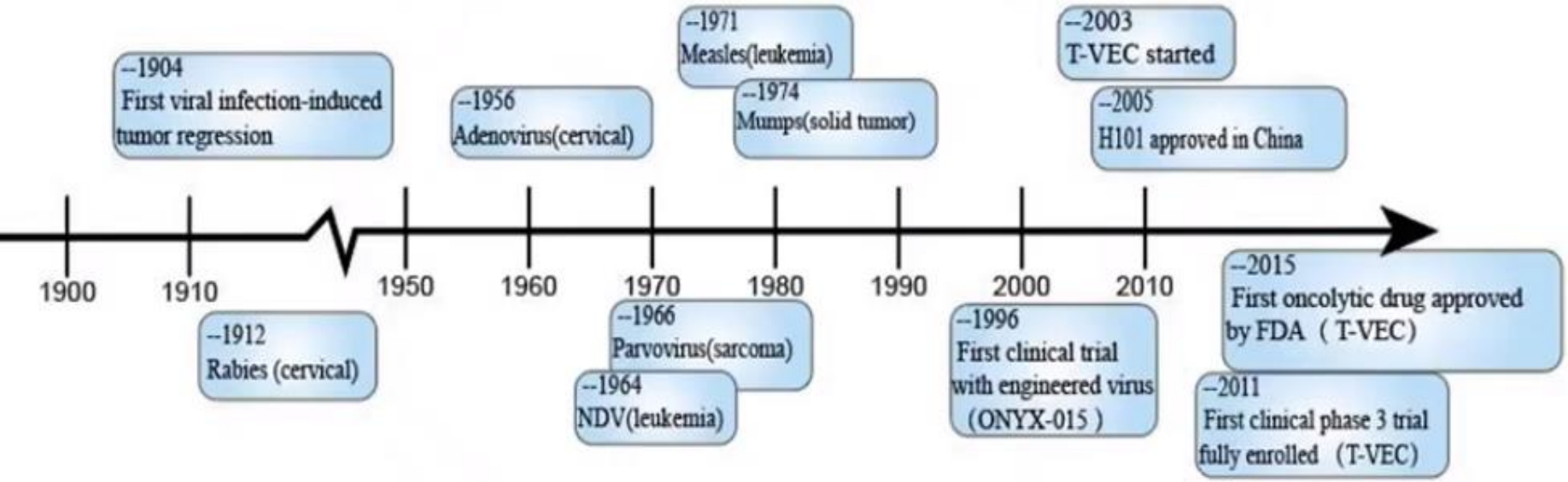

Conscious of potential application as a cancer therapy → Interest in oncolytic viruses waned due to side effects → Genetic engineering lead to viral therapy from laboratory to bedside → The first oncolytic virus approved by the FDA

Oncolytic viruses (OV) – Mechanism of Action

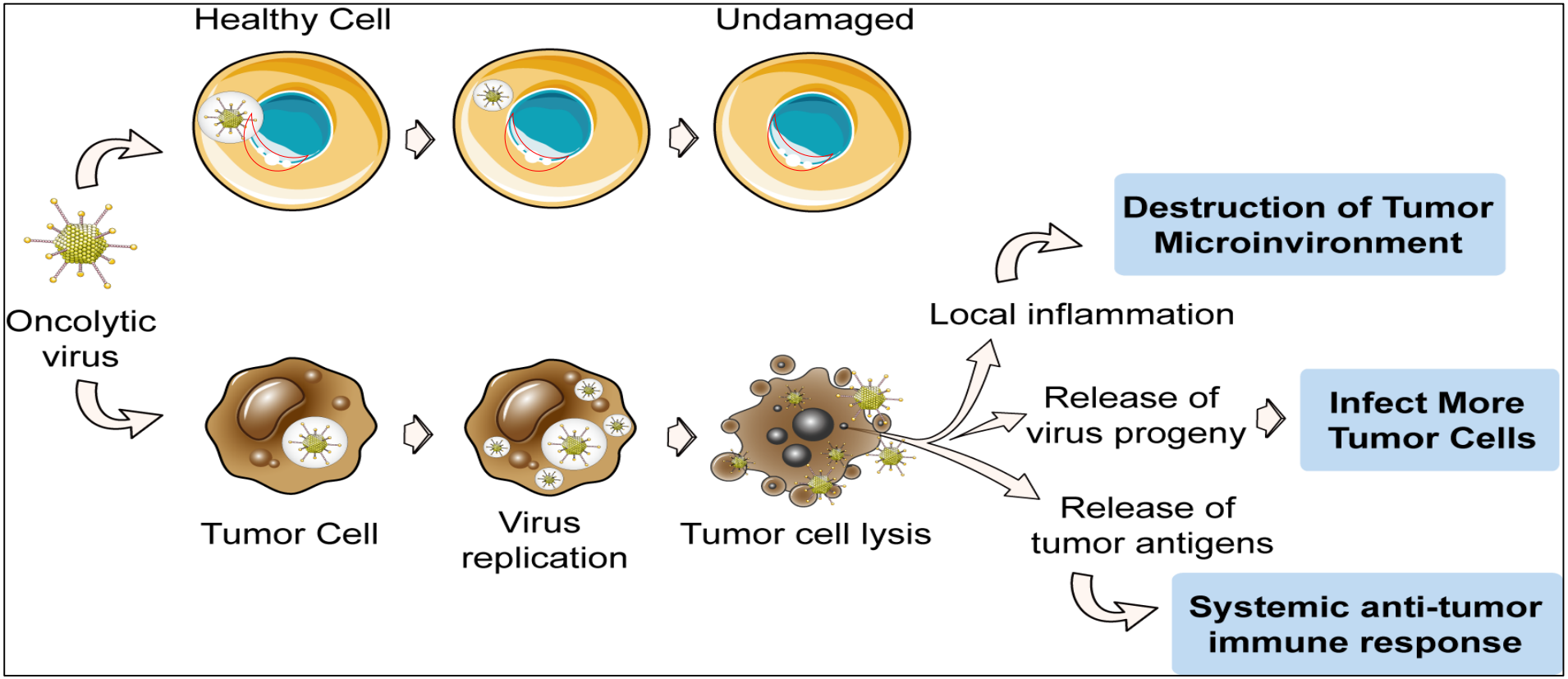

- **OV do NOT attack healthy cells = Targeted Treatment**
- **OV have a double therapeutic effect:**
  - **Direct tumor killing (oncolytic effect)**
  - **Systemic anti-tumor immune response (immune stimulating effect)**

Virotherapy - Mechanisms of Action

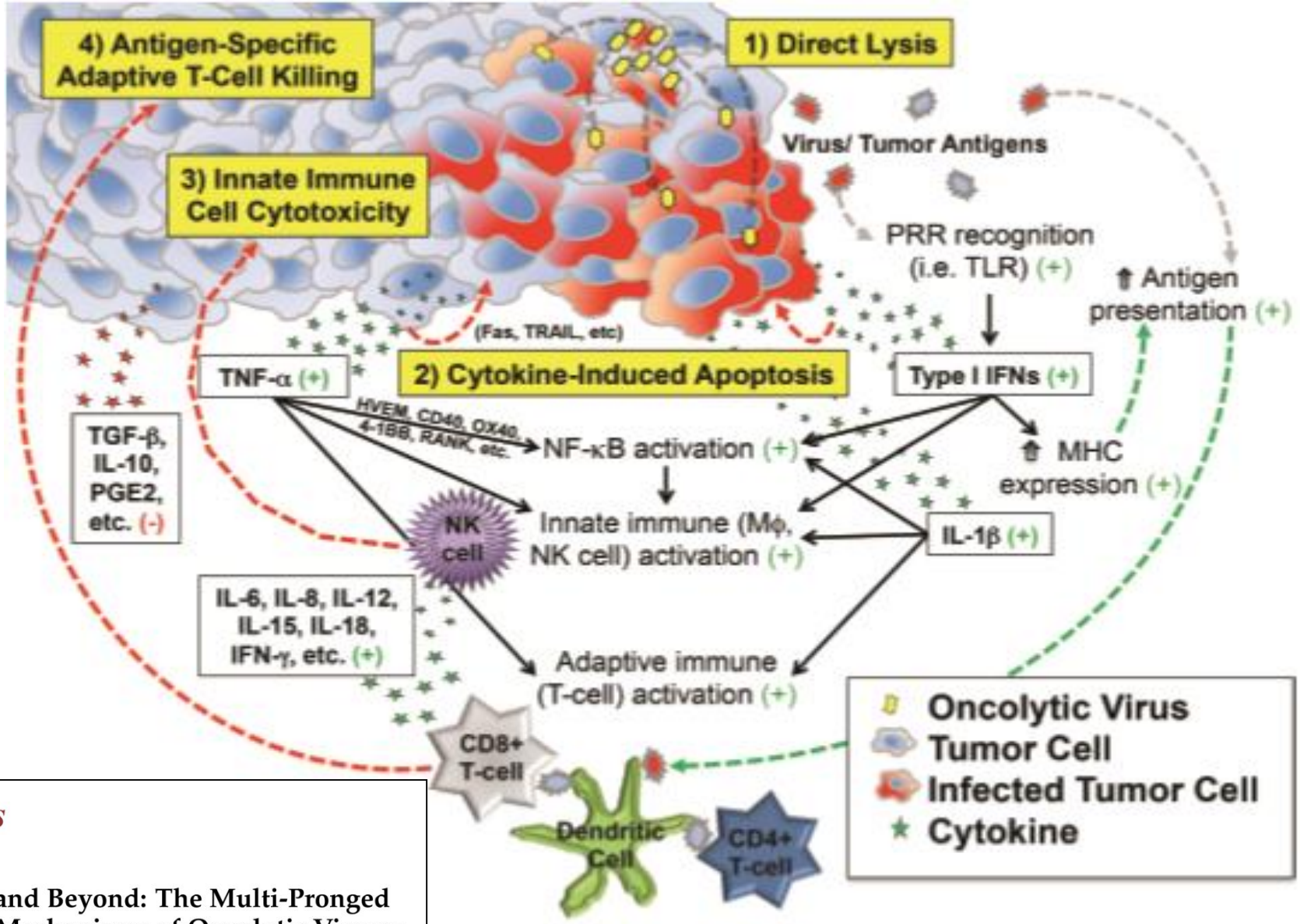

viruses

Review

To Infection and Beyond: The Multi-Pronged Anti-Cancer Mechanisms of Oncolytic Viruses

Kevin A. Cassady [1,2], Kellie B. Haworth [1,3], Josh Jackson [4,5], James M. Markert [5] and Timothy P. Cripe [1,3,*]

Oncolytic viruses (OV) – Mechanism of Action

Mechanisms of Tumor Tropism --Abnormal cell receptors

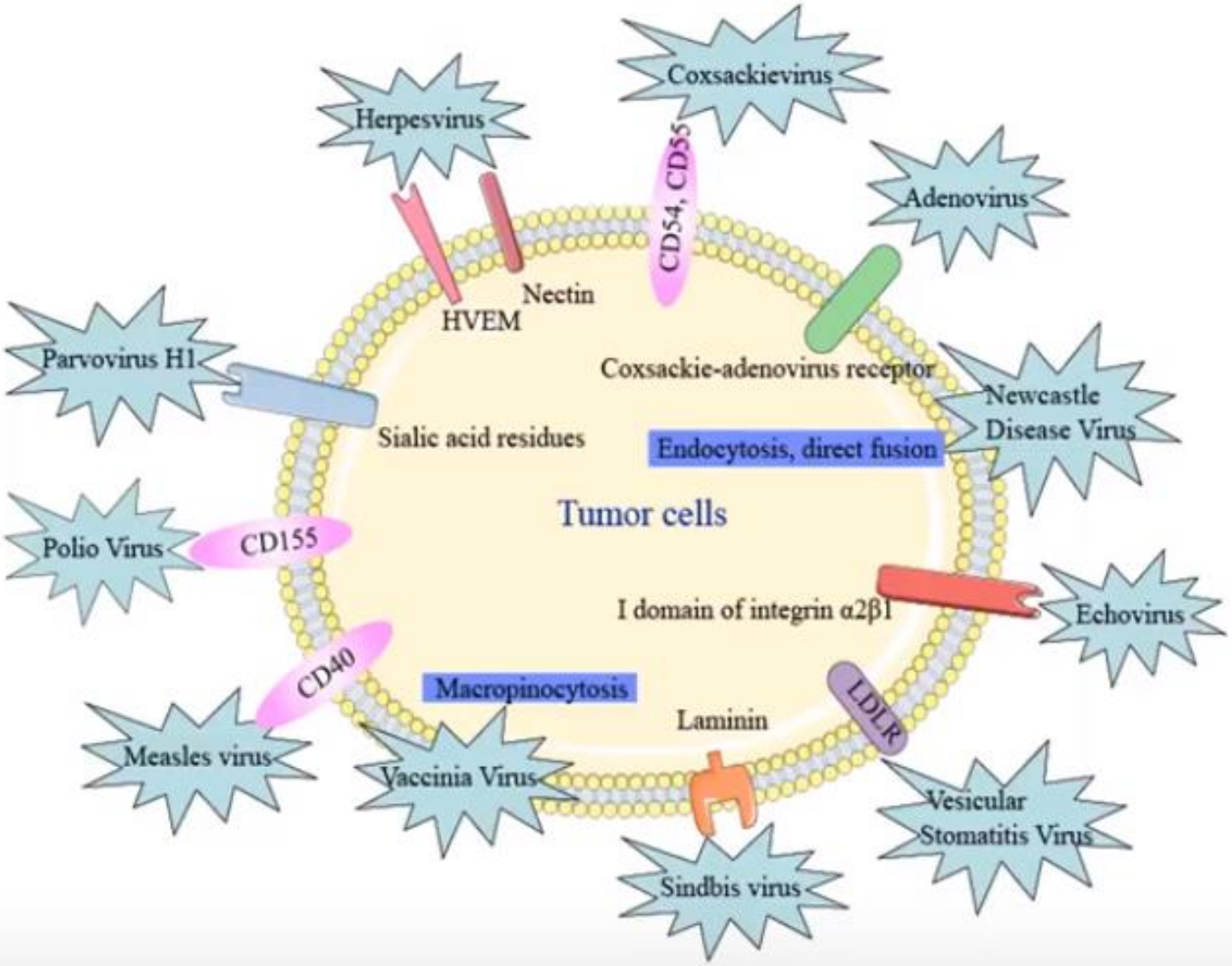

VOLUME 33 · NUMBER 25 · SEPTEMBER 1 2015

JOURNAL OF CLINICAL ONCOLOGY

UNDERSTANDING THE PATHWAY

Oncolytic Virus-Mediated Immunotherapy: A Combinatorial Approach for Cancer Treatment

Sean E. Lawler and E. Antonio Chiocca, *Brigham and Women's Hospital, Harvard Medical School, Boston, MA*

See accompanying article on page 2780

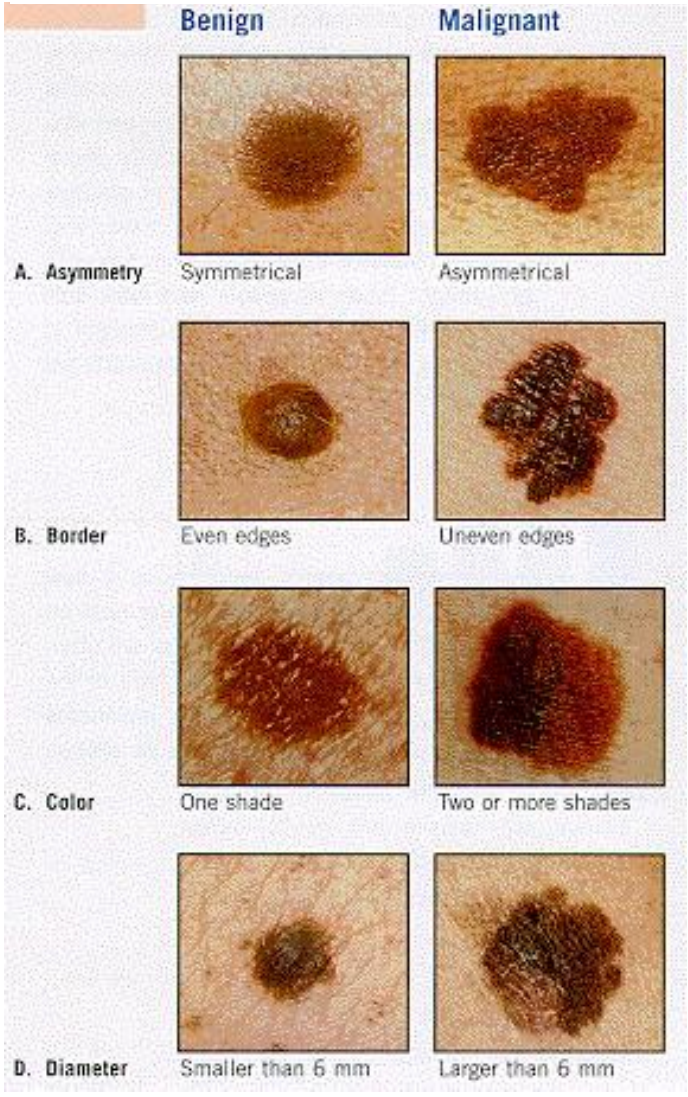

Rigvir®
Echovirus Echo-7
2004 Riga, Latvia
approval

Imlygic®, T-VEC
Herpes virus
Intralesional
2015 AMGEN

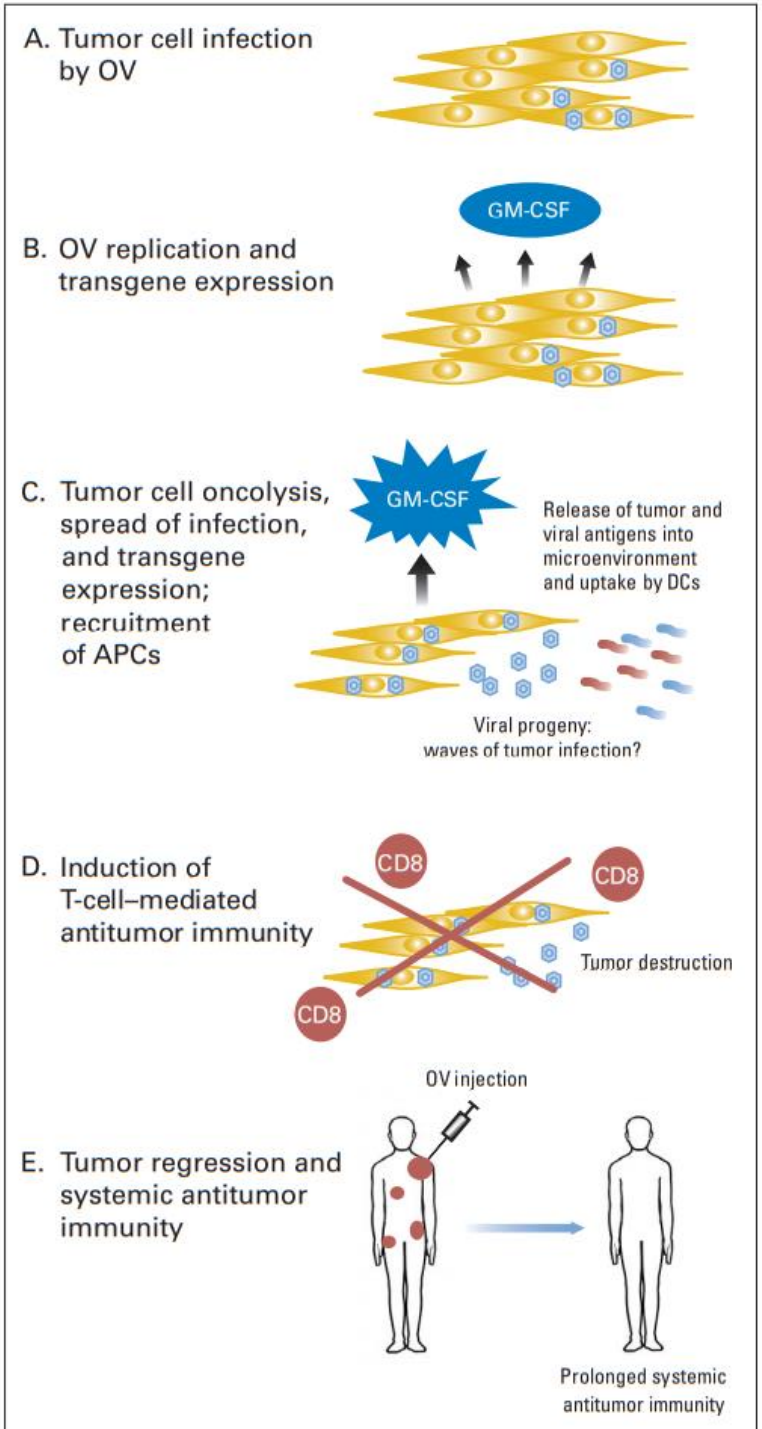

Oncolytic viruses (OV): inherent or engineered?

- Inherent oncotropic

Inherent

Newcastle Disease Virus,
Vesicular Stomatitis Virus,
Parvovirus,
Coxsackievirus,
Reovirus.

- Selectively target tumor cells
- Decrease pathogenicity to normal cells
- Decrease the antiviral immune response
- Increase the antitumor immune response.
- Increased adverse events?

Engineered

Herpes Simplex Virus,
Adenovirus, Poliovirus,
Vaccinia Virus, Influenza Virus,
Measles Virus,
Vescilar Stomatitis Virus,
Adeno-Associated Virus.

Oncolytic viruses used for GBM treatment

- ✓ **Polioviruses** (PVS–RIPO)
- ✓ **Adenoviruses** (ONYX-015, DNX2401/DELTA-24-RGD)
- ✓ **HSV** (G207, HSV1716, M032, G47Δ)
- ✓ **Reoviruses** (Reolysin™)
- ✓ **Paramyxovirus** (Measles, NDV)
- ✓ **Parvovirus** (ParvOryx)

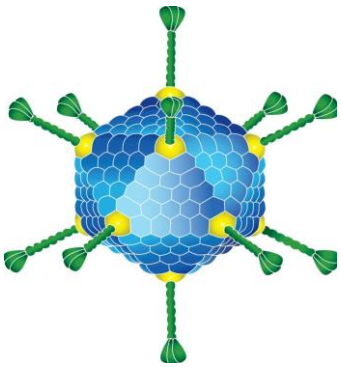

Structure of Polio

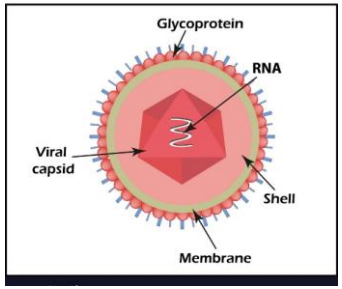

Cancer J. 2012 ; 18(1): 69–81. doi:10.1097/PPO.0b013e31824671c9.

Oncolytic Virus Therapy of Glioblastoma Multiforme – Concepts and Candidates

Guido Wollmann, MD[1], **Koray Ozduman, MD**[2], and **Anthony N. van den Pol, PhD**[1]
[1]Department of Neurosurgery, Yale University School of Medicine, New Haven, CT 06520
[2]Department of Neurosurgery, Acibadem University School of Medicine, Istanbul-Turkey

HERPESVIRUSES

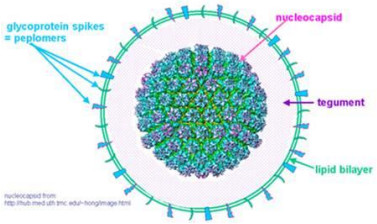

PRESENTATION OUTLINE

1. **GBM – Treatments, Challenges & Outcome**
2. **GBM: New Strategies with OV, DC, CPI**
3. **GBM and OV – Presentation of 4 Patients**
4. **Discussion of the New GBM Protocol**

   & Clinical OV Program

5. Case Reports: GBM treated with OV/DC (OV – DC)

OV only	***OV & DC & CPI***
Case #1	**Case #3**
Case #2	**Case #4**

Between 1-6 months
between 6-12 months
12-30 months
30-60 months
> 60 mo = 5 years

Archimedes von Syrakus

“Classical” Treatments

Case #1

F.W. (F) 1956
GBM 10/2010

10/10 7/11

GBM **Relapse**

Clinical Data

Grand-Mal seizures

Hemi plegia L

Complains

Imaging

10/10-MRI: 38*29 mm

7/11-MRI: Progression

11/11-MRI: Progression

Therapies

“Total Resection”

Stereotactic radiation 6x5Gy

11/05-1/06 Rad-Temodal

7/11 Temodal

CCNU + Procarbazin Plt↓→stopped

"Classical" & "Biological" Treatments

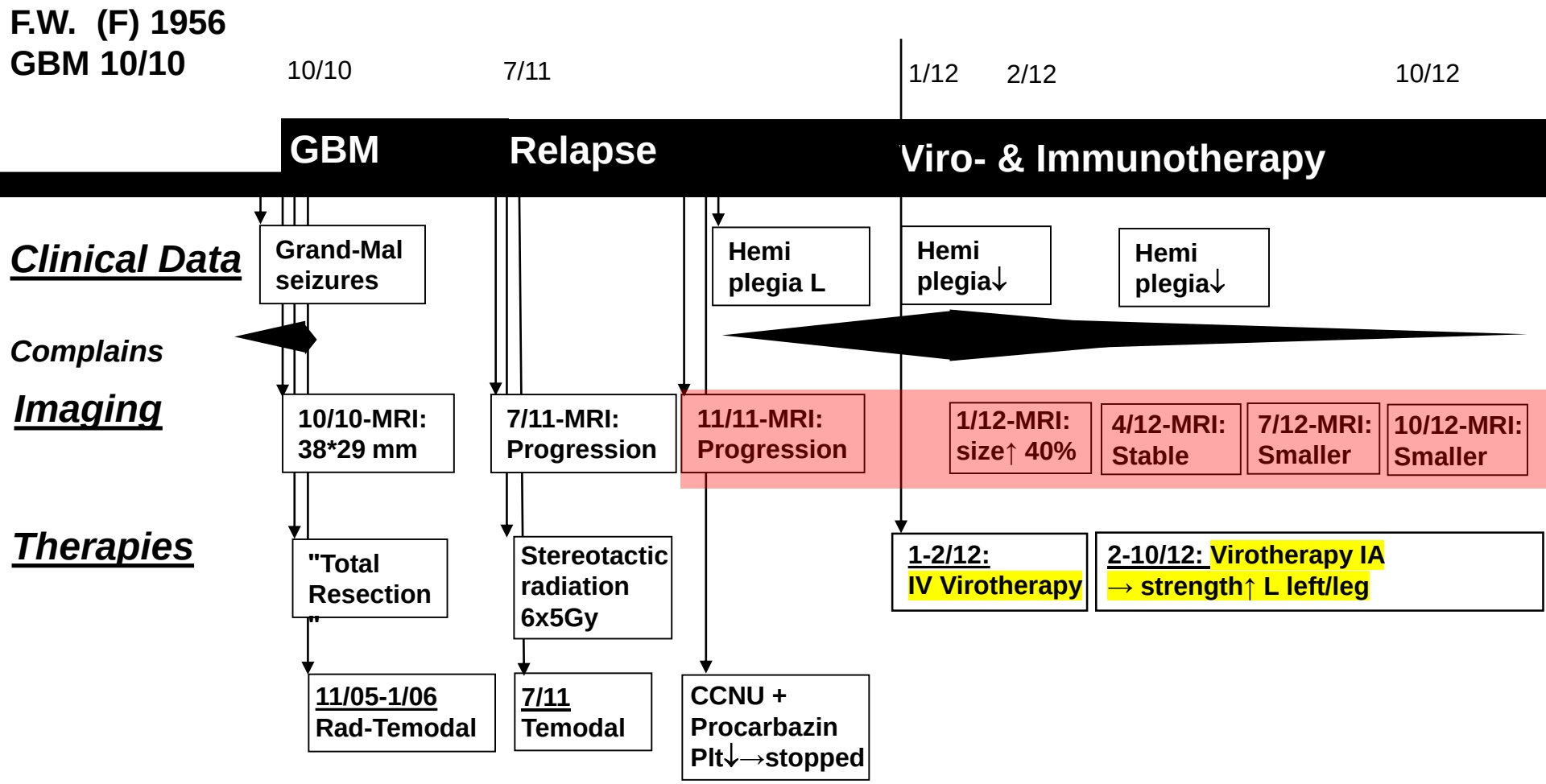

Glioblastoma multiforme Grad 4 rechts frontal (10/10) mit Rezidiv (7/11)

F.W., ♀, *01.10.56

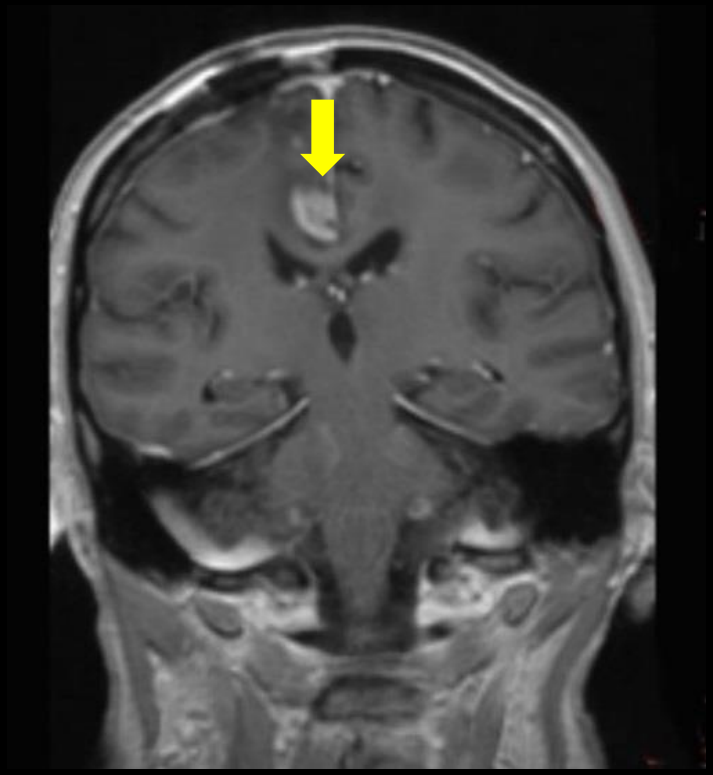

15.11.2011

Größenzunahme des Rezidivs
trotz Operation, Radio-Chemotherapie mit Temozolomid, Cilengitide, stereotaktischer Bestrahlung und Dosis-intensivierter Chemotherapie mit Temozolomid

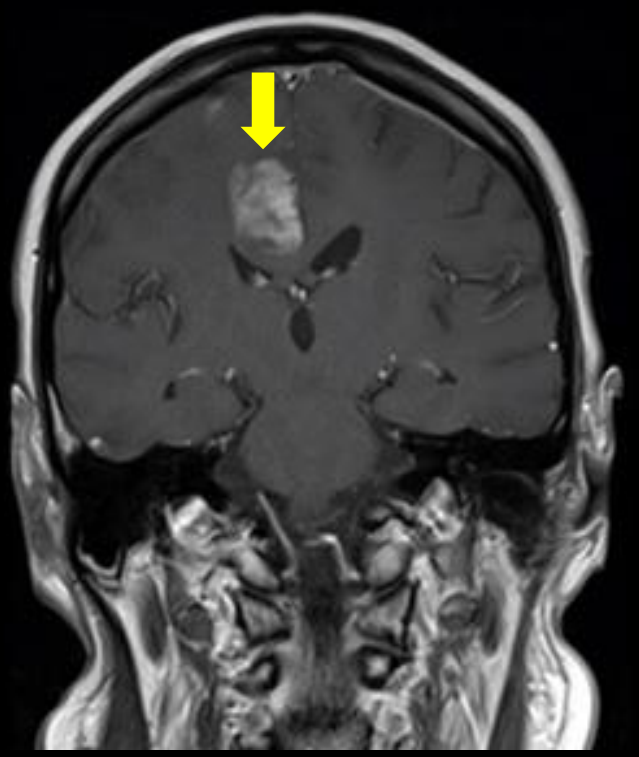

23.12.2011

Verdoppelung des Tumorvolumens in 5 Wochen!

09.01.12 Beginn der Virotherapie

23.12.2011

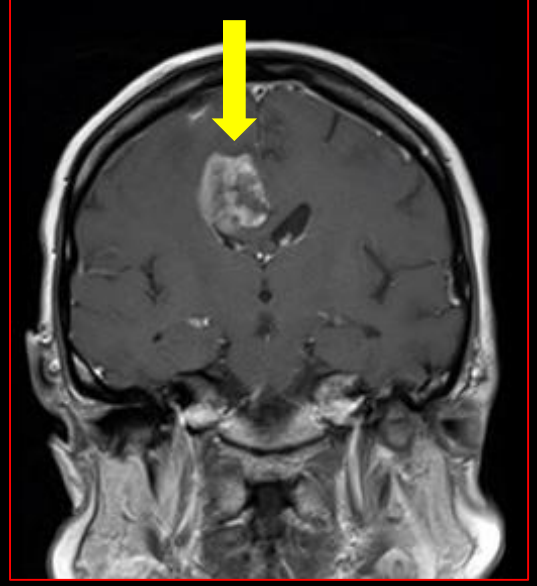

30.01.2012

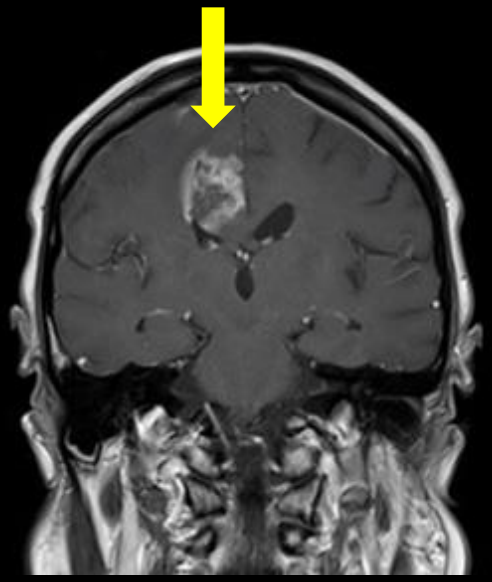

02.04.2012

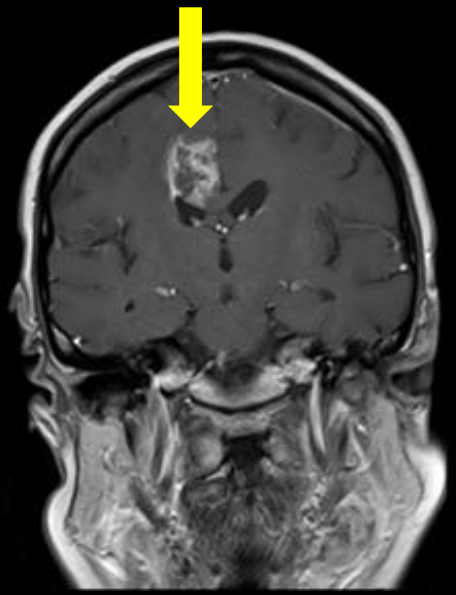

08.06.2012

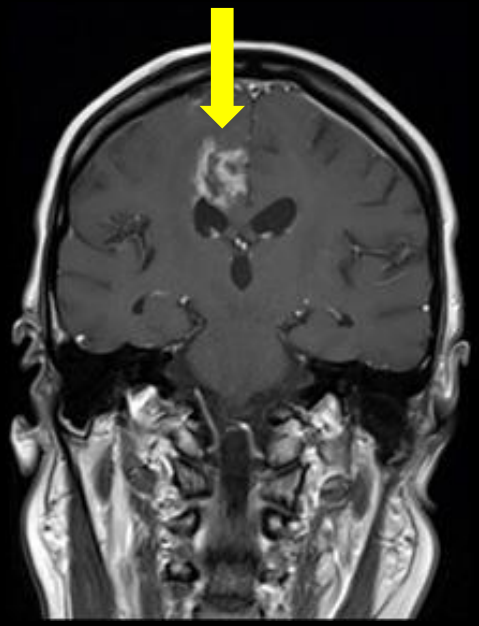

25.07.2012

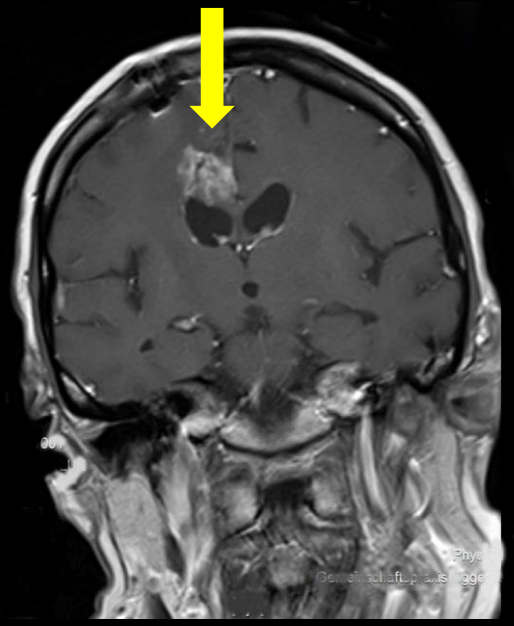

01.10.2012

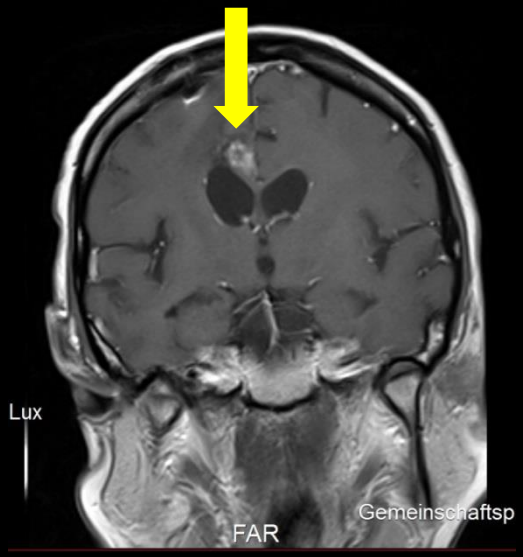

28.01.2013

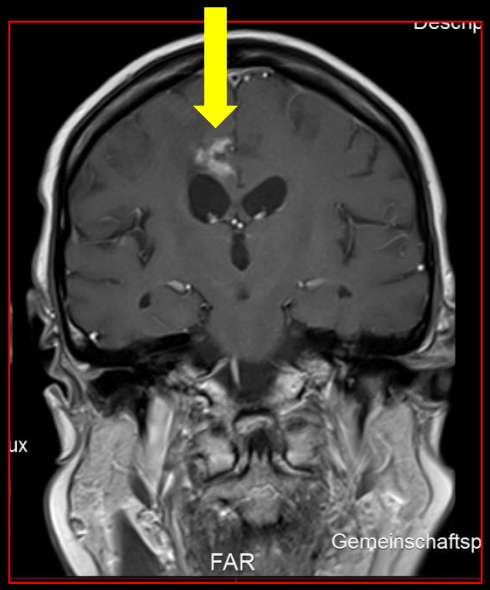

11.03.2013

22.04.2013

01.07.2013

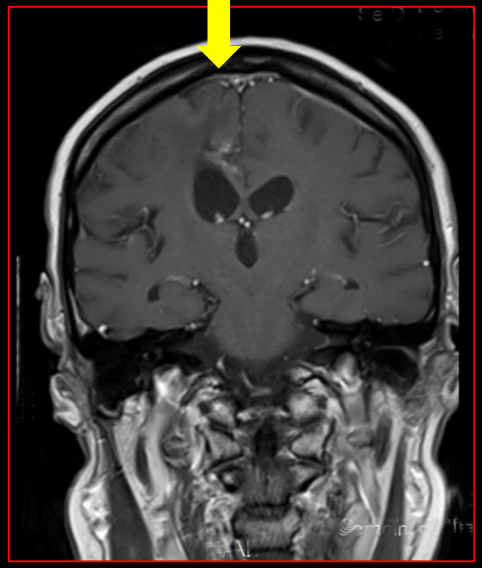

02.10.2013

07.01.2014

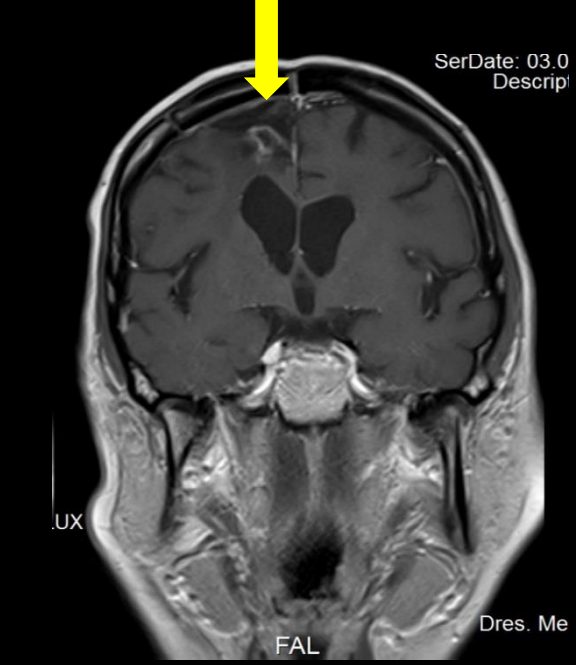

03.04.2014

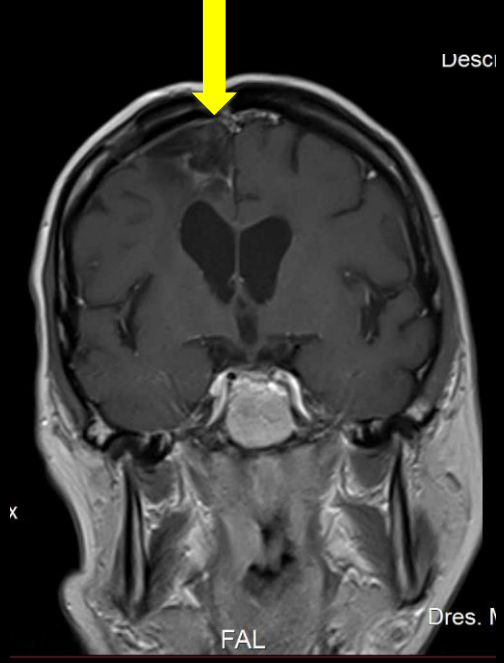

07.07.2014

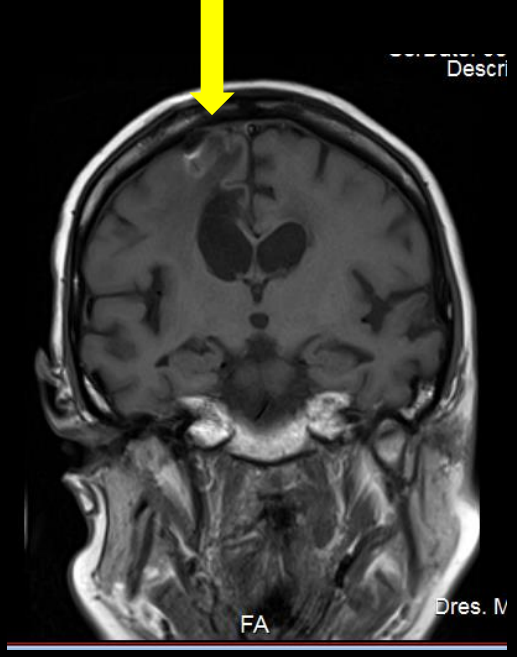

06.10.2014

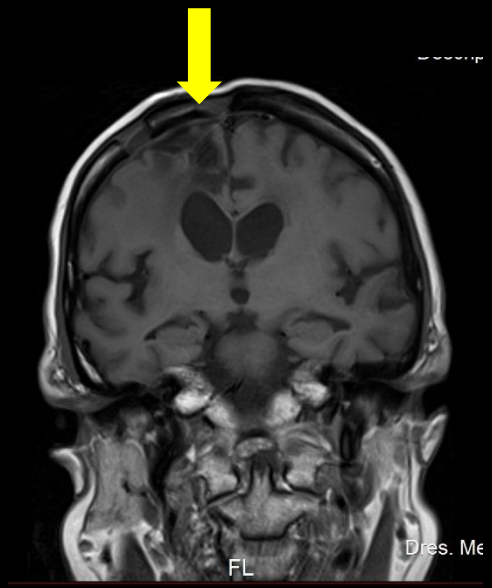

07.01.2015

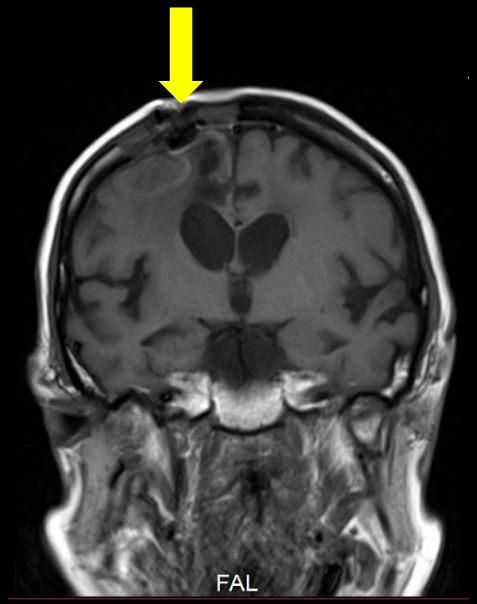

08.04.2015

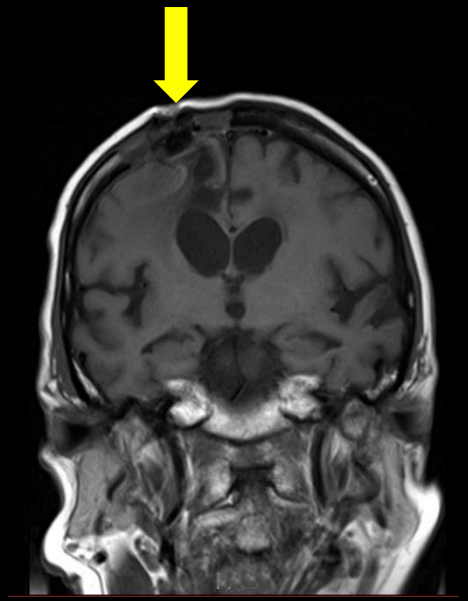

12.10.2015

F.W. (F) 1956
GBM 10.10

Axial T1 + Gd

Presentation | **Relapse** | **1.2012- Viral Therapy initiated**

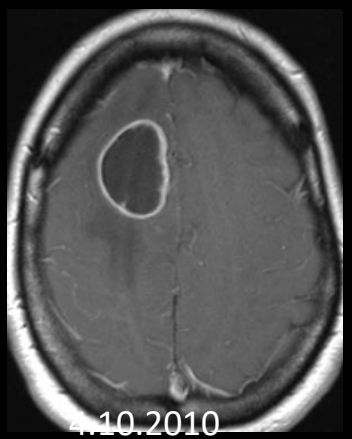

4.10.2010

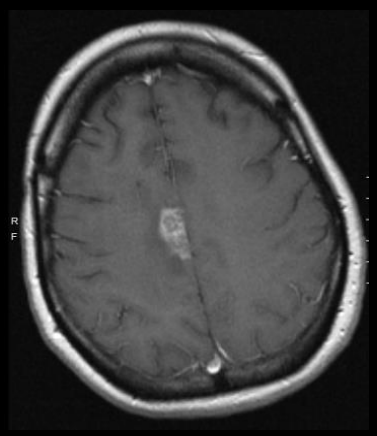

15.11.2011

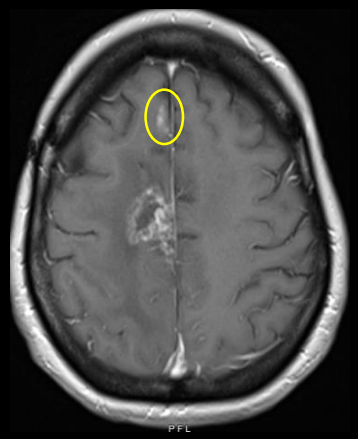

2.4.2012

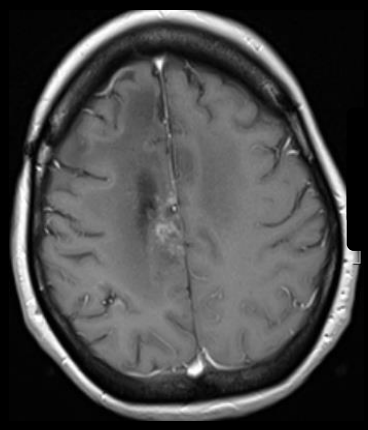

28.1.2013

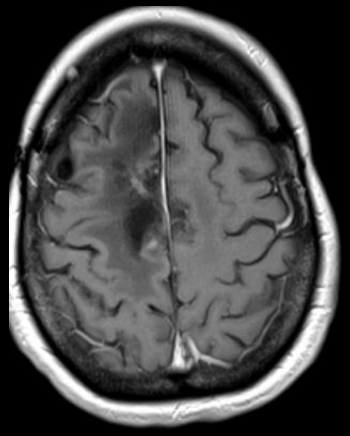

14.1.2016

Positive & Negative Control

"Classical" & "Biological" Treatments

Case #2

G.P. (F)
GBM

6/05 | 10/05 | 3/06 | 5/08 | 7/09 | 10/09 | 6/15 | 10/15

Diagnosis of GBM & Initial Tx → **1st Tx Round Immunotherapy** → **Relapse & 2nd Tx**

Clinical Data

Speech↓, Weak R leg, Balance↓, Headache

Pregnancy + Delivery

Speech↓, hemisphere↓, Hemianopsy, epilepsy

Complains

Imaging

MRI (date) 12*13*15

MRI shrinkage

Therapies

"Total Resection"

11/05-1/06
Rad-Temodal
Plt↓

10/09
- **VIROTHERAPY**

EEG patho

EEG Normal

27-31/7/15
VIROTHERAPY

7/9/2015-4/2016
- **VIROTHERAPY**
- **Nivulomab**

T1 + Gd

26-6-2015

16-11-2015

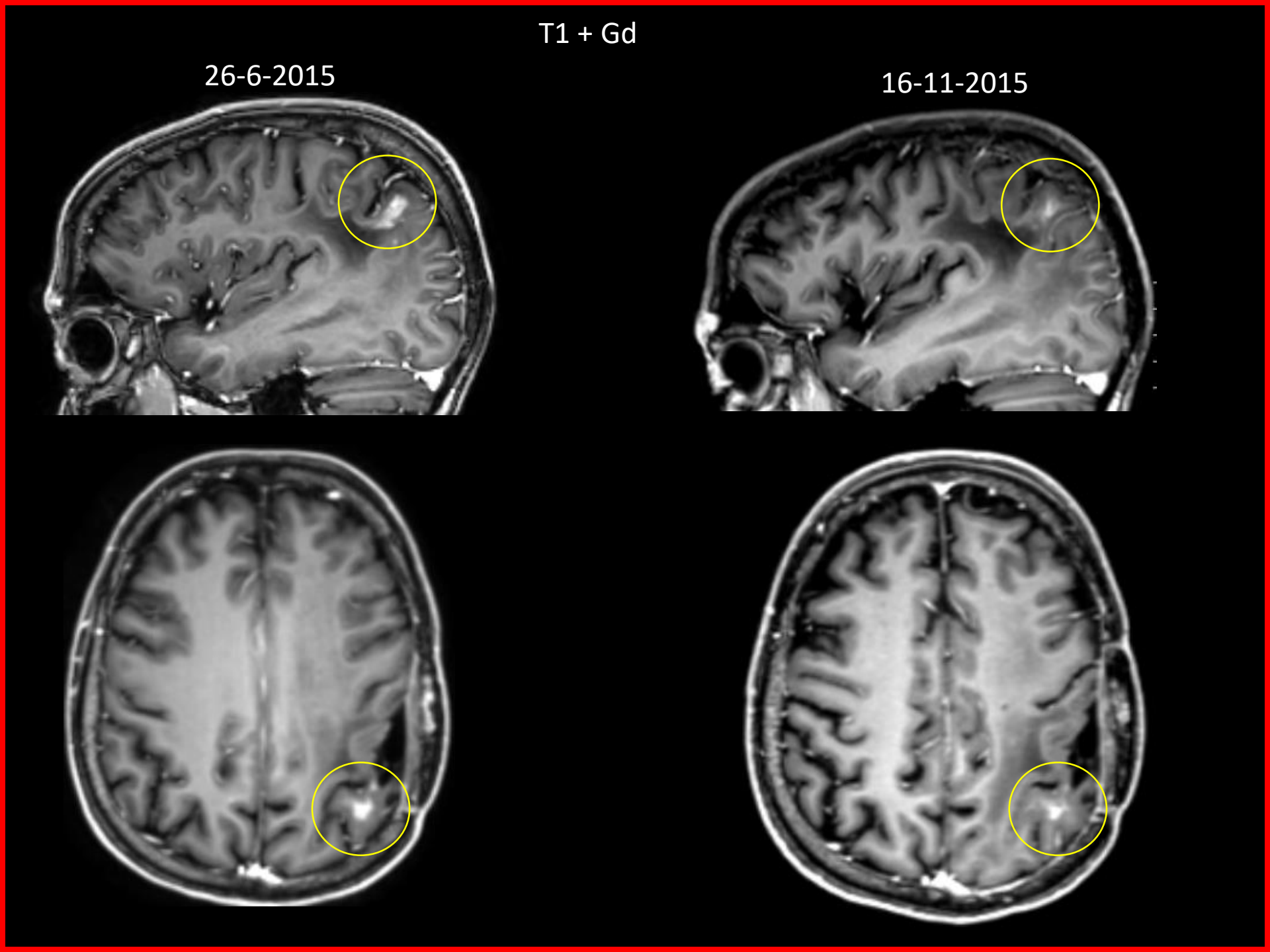

S.D. 18.7.1968
GBM (MGMT-neg)

Case #3

19/1/2011 | 5/2012 | 8/2012 - | 10/2017

GBM | **Relapse** | **Viro- & Immunotherapy**

Clinic

Headache
L leg weak

(no clinical complaints)

Imaging

19.1.2011 = MRI:
SOL 48x42x36 mm, right temporal

16/5/2012 = MRI:
Relapse 13 mm
Right temporal

Since 2/2014 MRI (q3 month) – No Evidence of Disease

Therapies

28.1.2011
"Total resection"

24/6/2012
2nd "Total resection"

8/2012 – 10/2017 IV VIROTHERAPY

28/8/2012-10/2016: Dendritic Cells (total 19x)

2/3/2011
Radiation/TMZ
+TMZ 6 cycles

T1+Gd 20/1/2011

T1+Gd 1/9/2011

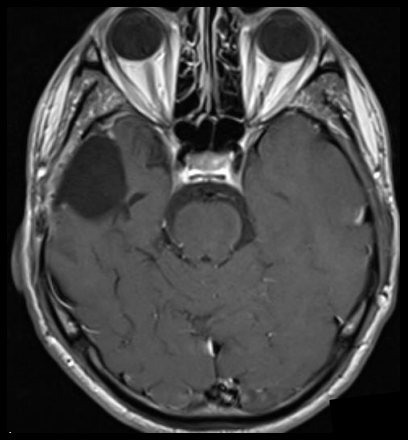

T1+Gd 25/6/2012

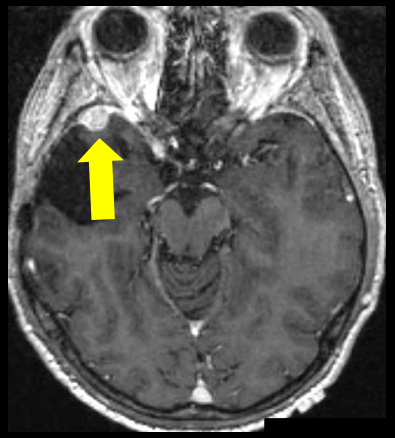

T1+Gd 20/7/2015

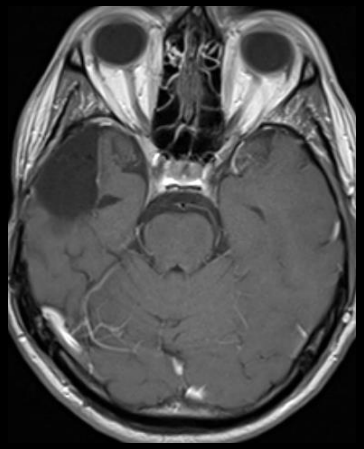

Coronal FLAIR 20/1/2011

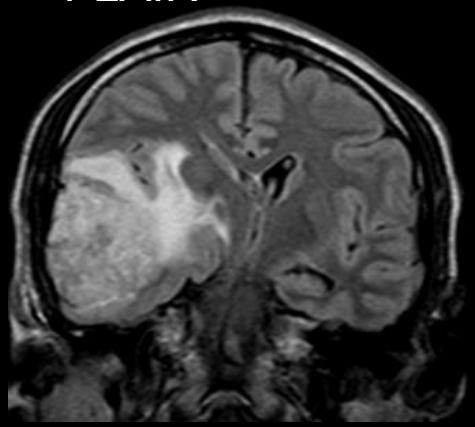

Coronal FLAIR 25/6/2012

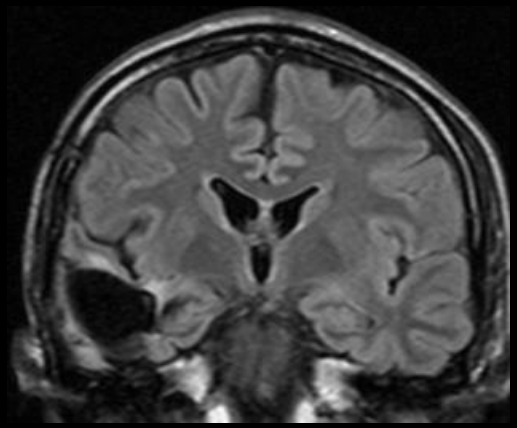

T1+Gd 20/1/2011

T1+Gd 1/9/2011

T1+Gd 25/6/2012

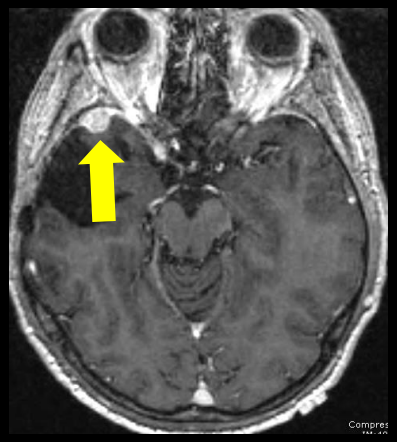

T1+Gd 20/8/2012

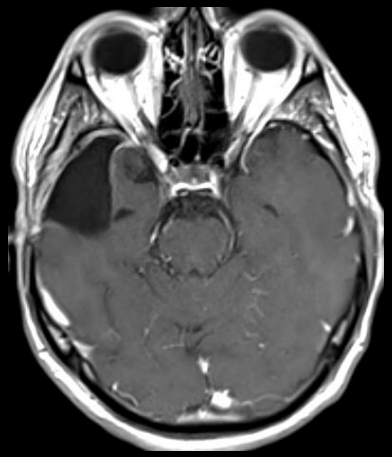

FLAIR 20/8/2012

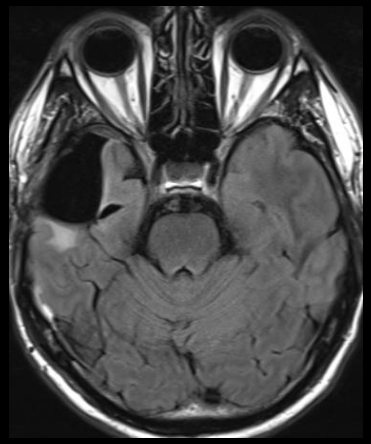

T1+Gd 23/9/2013

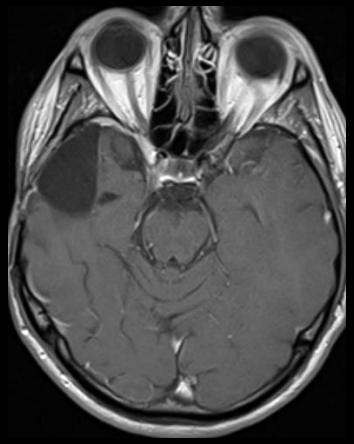

T1+Gd 20/4/2015

T1+Gd 20/7/2015

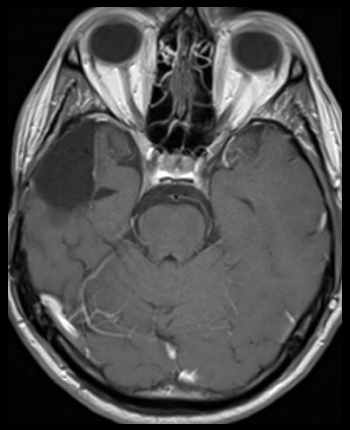

Case #4

K.F. Male Patient DOB = 1969
Glioblastoma multiforme (GBM),
MGMT + IDH-1/2 wild type

10.15 | 7.11 | 1.2.17

Diagnosis of GBM & Initial Tx

Clinical Data

- Hemiparesis R leg↓
- 25.7.16: 50% back to work Construction
- 1.2.17: 100 % back to work construction

Imaging

- MRI (14.10.15) L frontal lesion
- MRI (12.12.15) NED
- MRI (6.4.16) 8x9x23 mm mass - relapse
- MRI (2.5.16) 2 new lesions in tumor bed
- MRI (30.8.16) Shrinkage of previous lesions FET/PET: Tumor vs post-RT changes?
- MRI (3.1.17) Shrinkage of previous lesions??? FET/PET: ???
- MRI (30.5.17) MRI – NeD FET/PET - Shrinkage of previous

Therapy

- 19.10.15 Total resection => Histol: MGMT- wild type
- 5.1.16- Radiation + TMZ (despite MGMT wild)
- 19.1.16–21.4.16 IA VIROTHERAPY
- 4.5.-17.7.16 IA VIROTHERAPY
- IA VIROTHERAPY

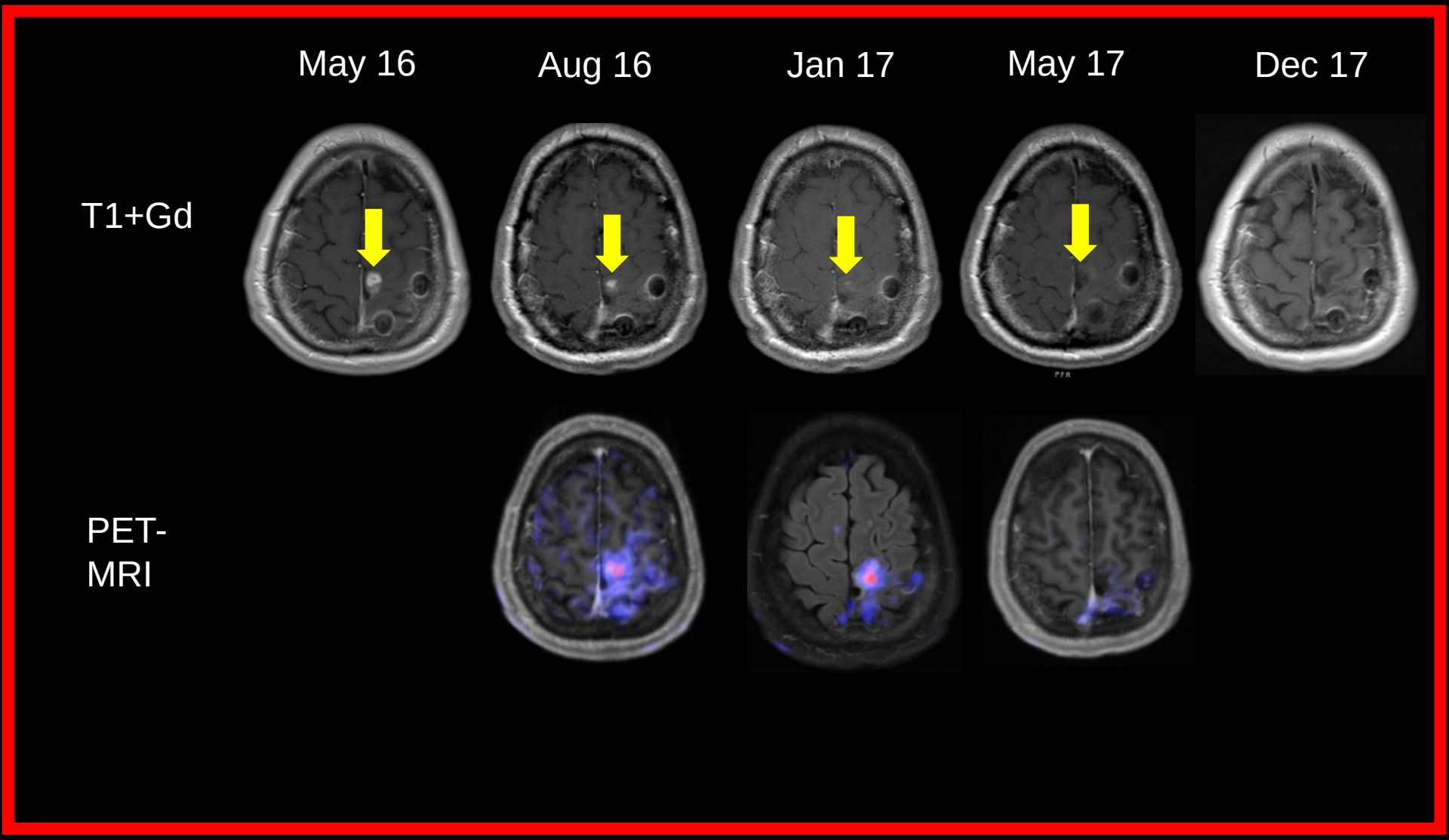
May 16
Aug 16
Jan 17
May 17
Dec 17
T1+Gd
PET-
MRI

Summary of 4 GBM Patients

PR = Partial Response
SD = Stable Disease
NED = No Evidence of Disease

Standard T_x for GBM

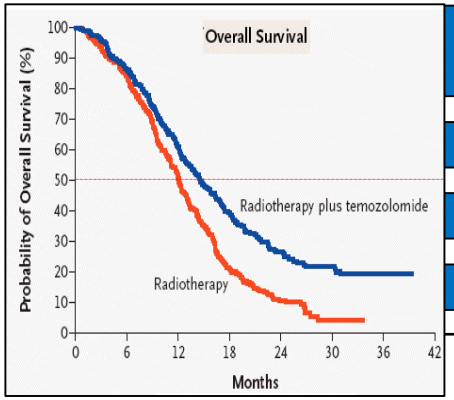

Viro- & Immunotherapy (n = 4)

#1: 54F 6 yr, died 8 mo after stopping Tx

#2: 33F 13y, PR, SD

#3: 43M 43y, NED x 7 yr

#4: 46M NED x 3.5 yr

4 5 6 7 8 9 10 11 12 13 14 15

Years

Clinical Experience Dr Arno Thaller

- ✓ GBM
- ✓ Breast Cancer
- ✓ Ovary Cancer
- ✓ Colon Cancer
- ✓ Pancreas Cancer
- ✓ Melanoma
- ✓ Prostate Cancer
- ✓ Lung Cancers
- ✓ Osteosarcoma
- ✓ Rhabdomyosarcoma
- ✓ Tongue Cancer
- ✓ ENT cancers

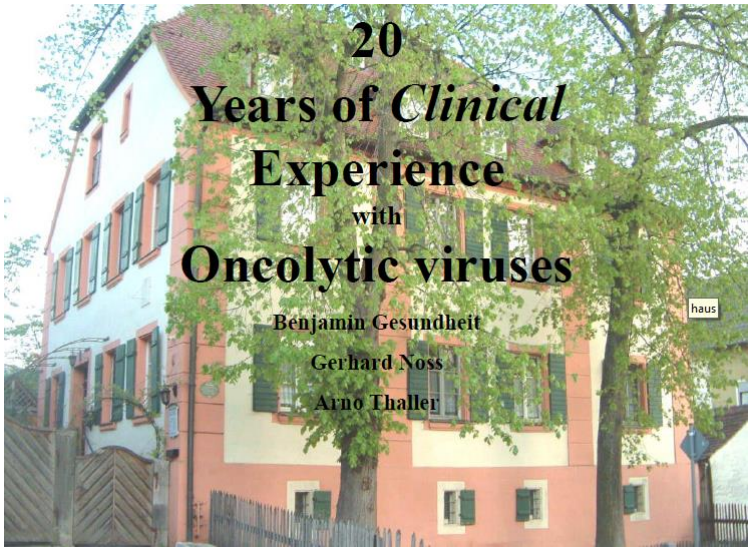

PRESENTATION OUTLINE

1. **GBM – Treatments, Challenges & Outcome**
2. **GBM: New Strategies with OV, DC, CPI**
3. **GBM and OV – Presentation of 4 Patients**
4. **Discussion of the New GBM Protocol & Clinical OV Program**

The Bench to Bedside Abyss



4 Case Studies

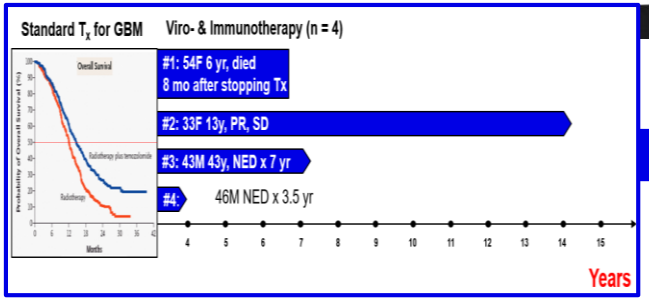

Plans & Future Considerations

Production

Protocol for treatment

Permits & Regulation

Place to Treat

Physicians Recruitment

Patients Recruitment

Pediatrics

Publications & Research

Payment & Funding

Personalized Treatment

Palliation → Prevention

Poland?

“Curative”

Protocol for GBM

Pediatrics & Adults

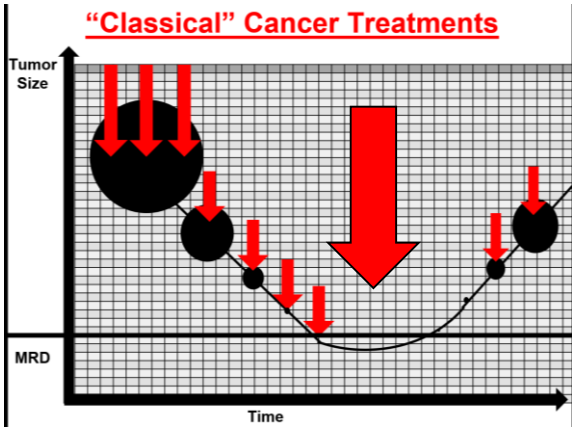

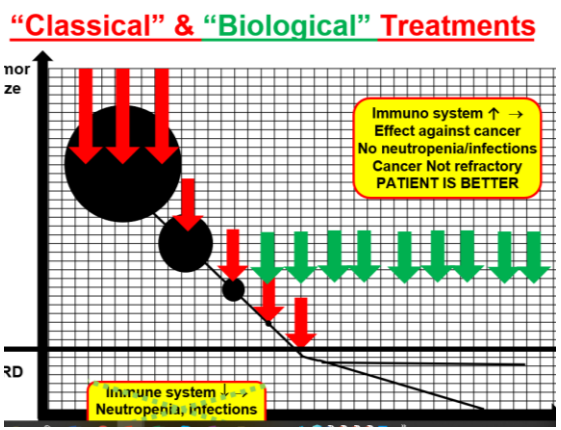

GBM Dx

Imaging

PET / MRI

Therapies

Total resection

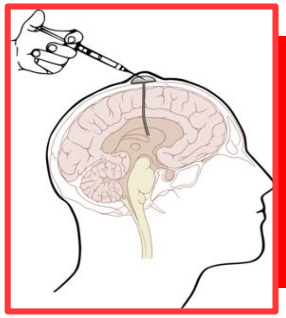

- **Ommaya Reservoir @ initial surgery**
- **OV, CPI**
- **Tumor cells (CTC),**
- **Immune Status, Viremia**

Stupp Protocol
Radiation + Temodal

Intra-arterial: OV, CPI



Summary & Future Directions

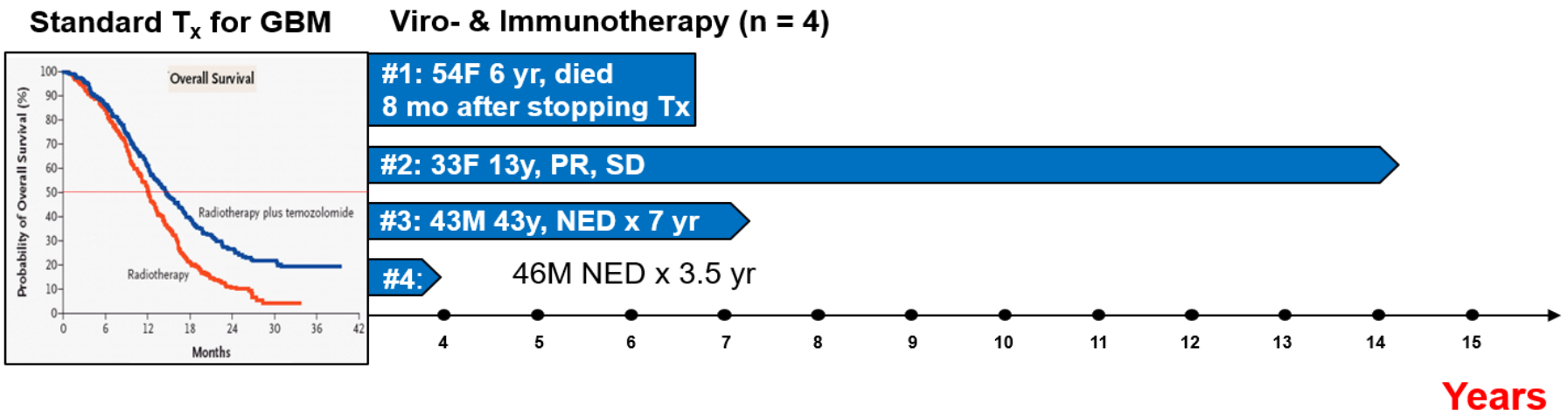

- **GBM is treatable**
- **Multi-center, multi-national Protocols: Early OV-Tx for GBM**
- **After classical GBM treatment (Sx, Rx, Temodal) => asap Viro- & Immunotherapy & CPI**
- **Immune monitoring before, during and after Tx**
- **Genetic Engineering for better Viruses?**
- **Genetic classifications of GBM for treatments?**
- **Virus specificity for various tumors "Virogram"**



Rabbi Yaakov Gesundheit
(1815-1878)
last chief Rabbi of Warsaw
(1870-1874)

Beni Gesundheit MD PhD,
RAPO YERAPE Ltd., ISRAEL
b.gesund@gmail.com
+972-506-558-638
www.Rapoyerape.com

rapo yerape Ltd.
Spreading Hope Virally

Warszawa, 10–11 stycznia 2019 roku



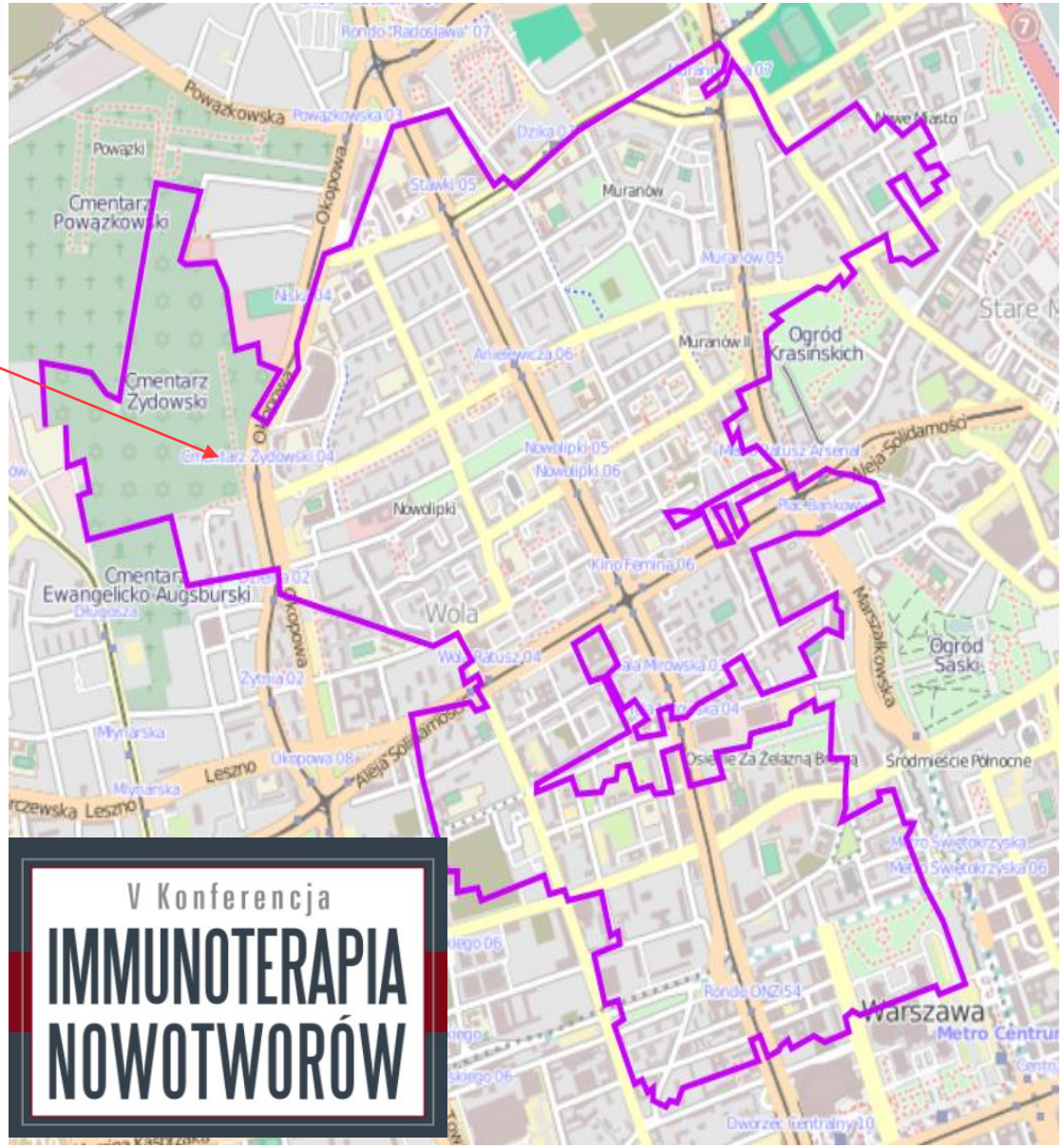

V Konferencja
IMMUNOTERAPIA NOWOTWORÓW

Beni Gesundheit
MD PhD CEO, CMO

Ron Ellis
PhD CTO

rapo yerape Ltd.
Spreading Hope Virally

Baruch
Labinsky CBO

Philip D.
Zisman PhD

Yehudit
Posen PhD

Ronny Pinkus
PhD, MBA:
VP CMC

Susan Suna

Nadya
Lisovoder MD

Beni Gesundheit MD PhD
Cell-El Ltd., ISRAEL
b.gesund@gmail.com +972-506-558-638
www.rapoyerape.com